


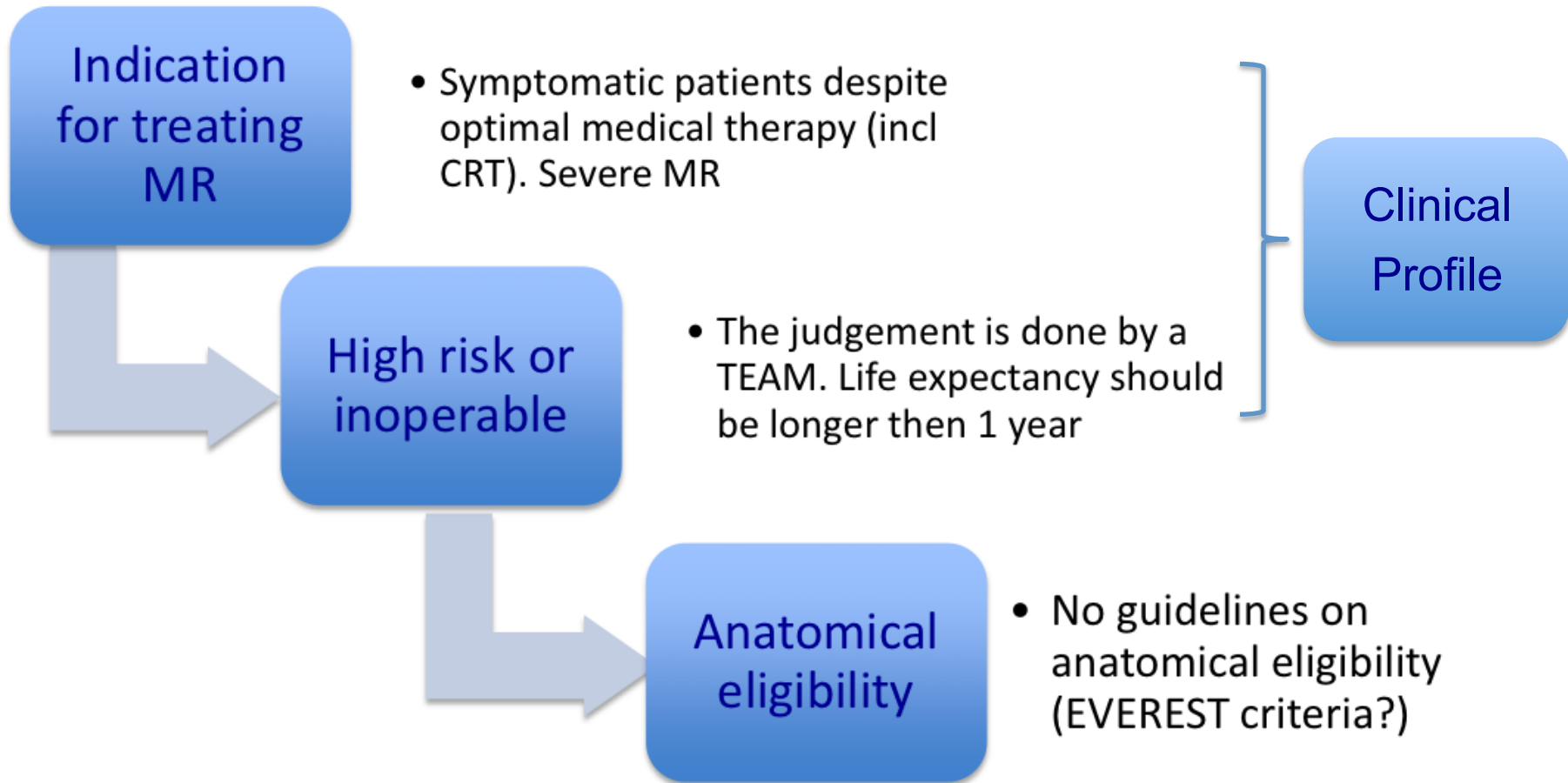
How to MitraClip: *Selezione del Giusto Paziente*

Eustachio Agricola

Responsabile Laboratori di Ecocardiografia,
Divisione di Cardiologia Clinica ed UTIC,
Ospedale San Raffaele, IRCCS, Milano



European guidelines reccommendation (IIbC)



Percutaneous Devices Landscape 2010/2014

➤ Edge-to-Edge

- MitraClip*

➤ Coronary sinus annuloplasty

- Cardiac Dimensions Carillon*
- Cerclage annuloplasty

➤ Indirect annuloplasty

- Ample PS3
- St. Jude AAR
- Mycor i-Coapsys

➤ Direct annuloplasty

- Mitralign*
- QuantumCor
- MiCardia ebCor
- Accucinch*

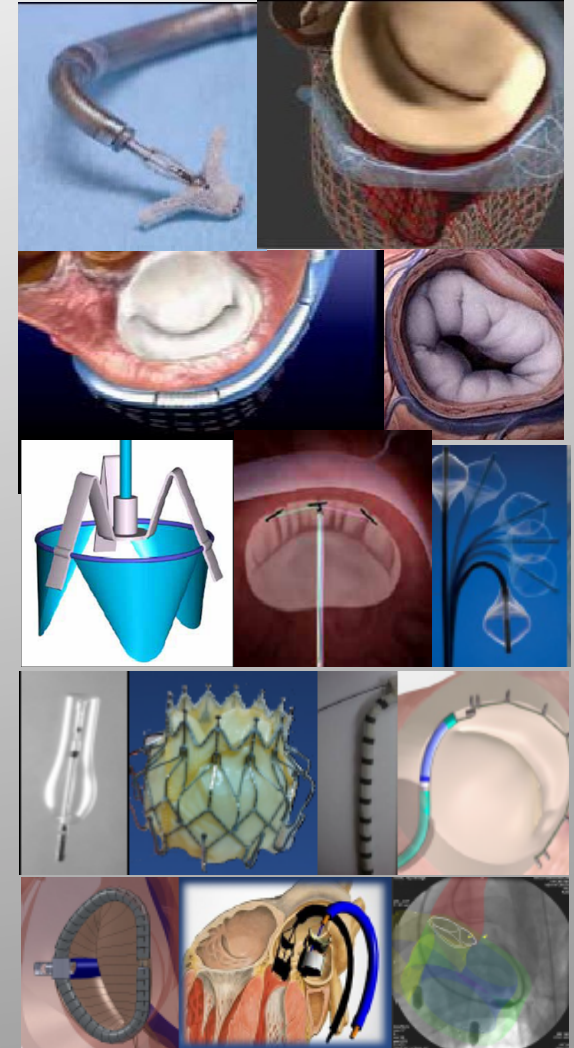
- ReCor (US)*
- Quantum Cor (RF)
- Valtech Cardioband*
- Micardia enCor

➤ Mitral valve replacement

- • EndoValve
- • CardiAQ*
- • Valtech Cardiovalve
- • ValveXchange

➤ Chordal shortening and other

- Cardiosolutions
- Mitra-Spacer*
- NeoChord
- Valtech VChordal



**in humans*

Tailored Options According to:

- Clinical Profile

- Etiology of MR

- Mechanism of MR

- Strict Anatomic Characteristics

Recommended anatomical criteria (from the EVEREST trial)

MR originates from the A2-P2 area

Coaptation length 2 mm

Coaptation depth 11 mm

Flail gap 10 mm

Flail width 15 mm

Mitral valve orifice area 4 cm²

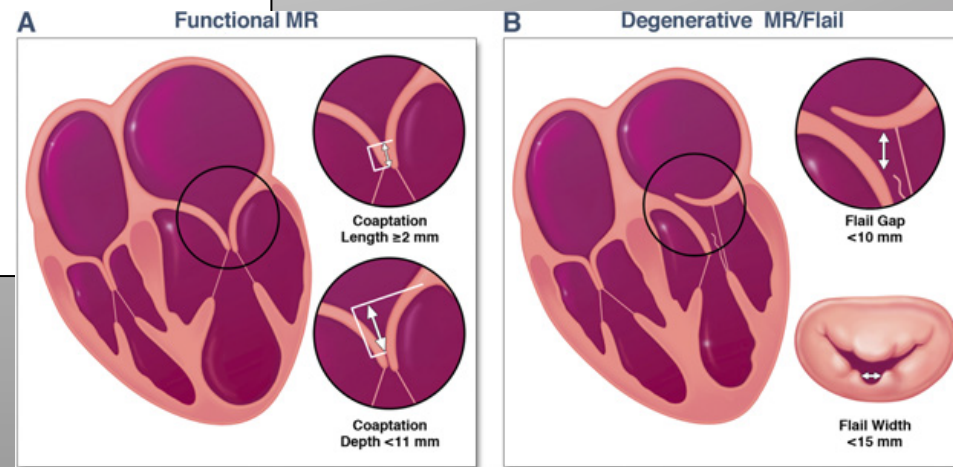
Additional criteria for caution

Short posterior leaflet (8 mm)

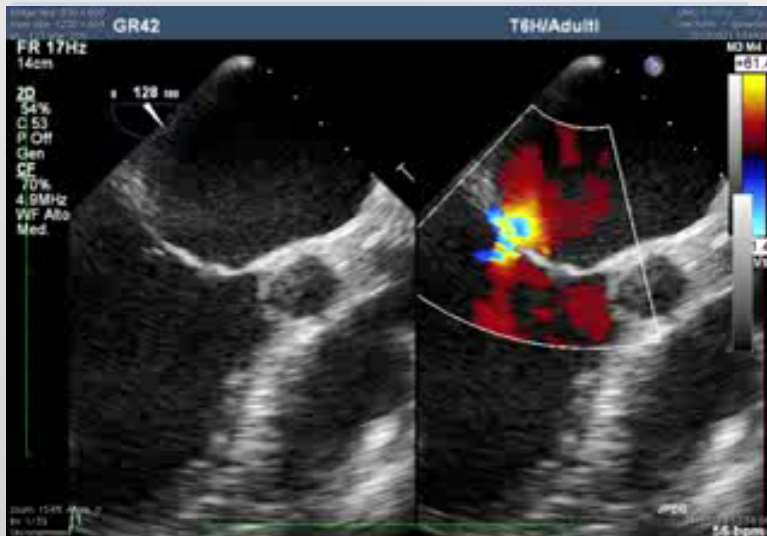Restricted posterior leaflet prolapse/flail width 15 mm

Calcification in the grasping area

Cleft or subcommissures in the area of the jet

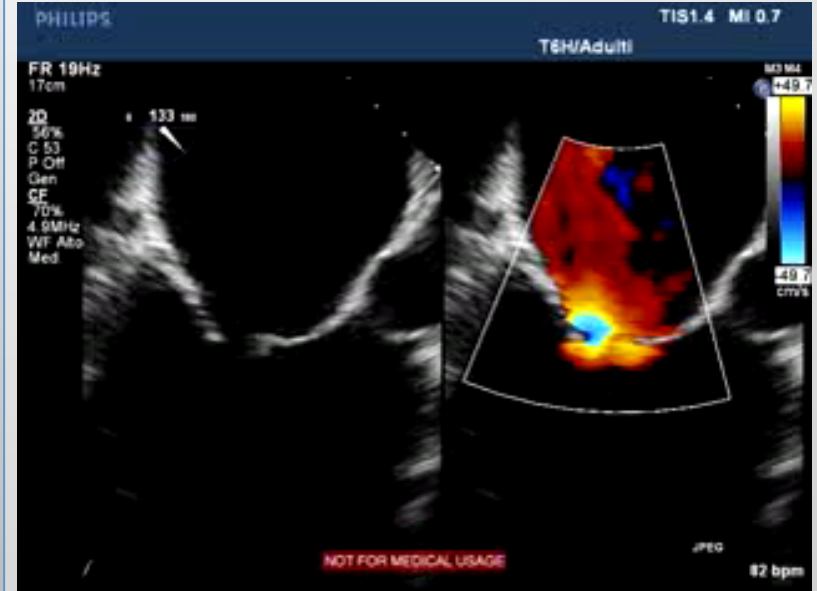


Etiology and Mechanisms



Type I (Prevalent)

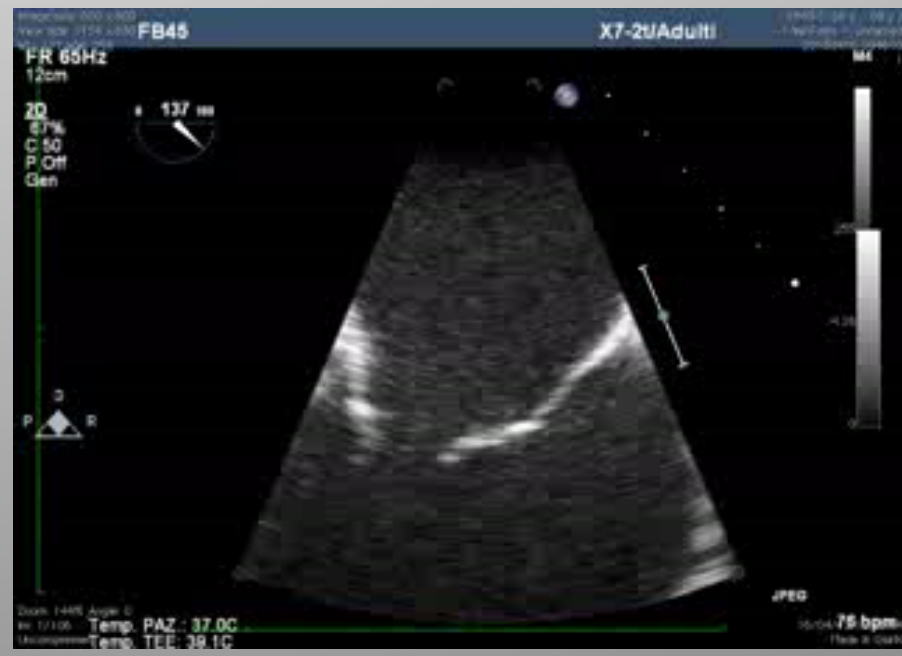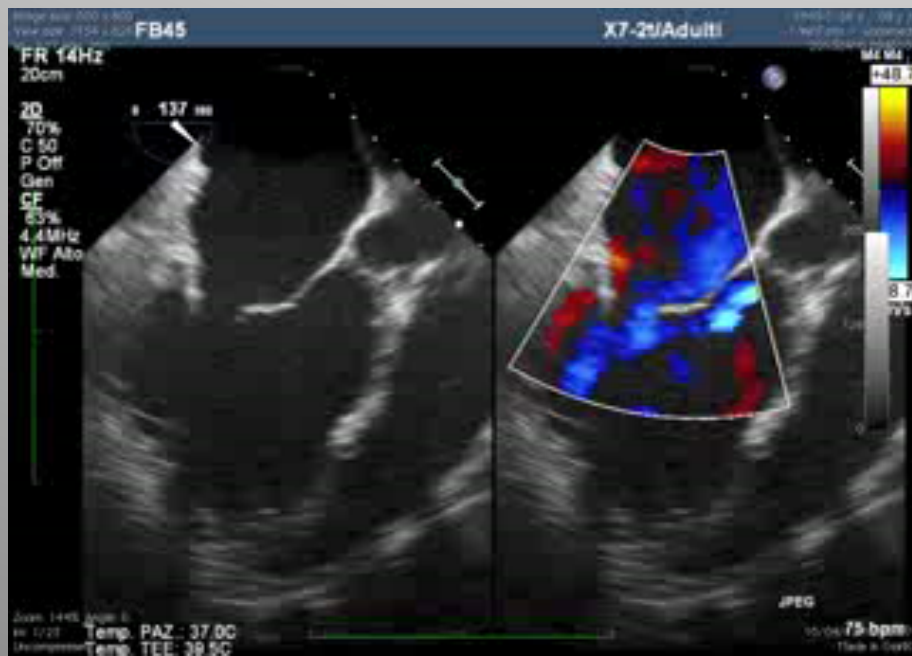
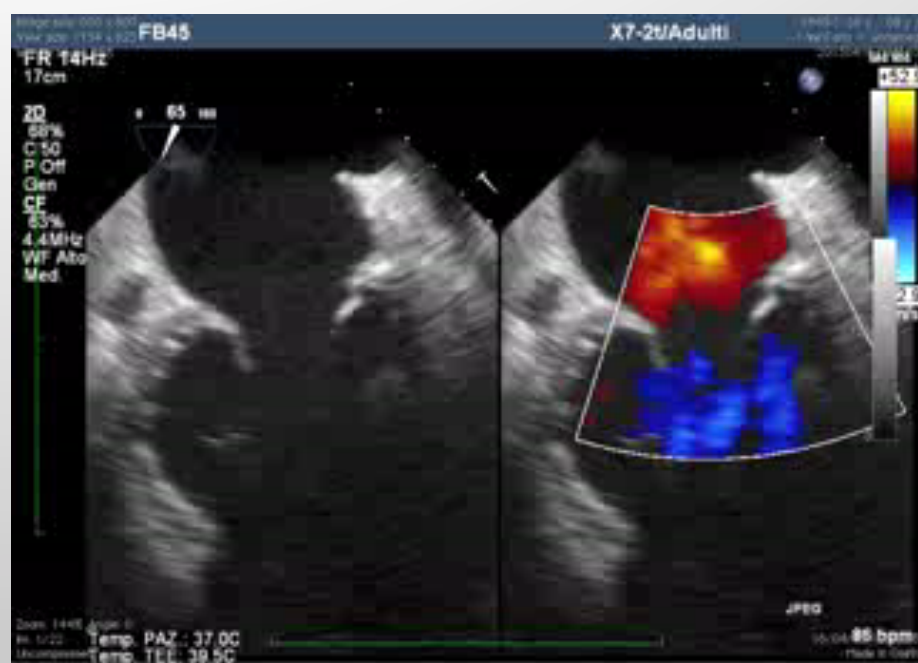
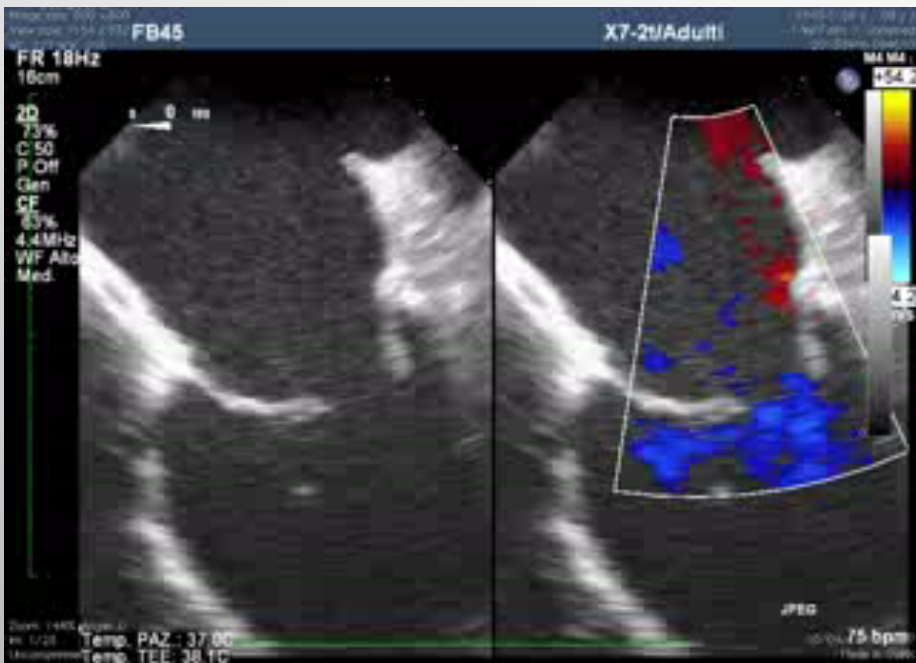
Annular Dilation



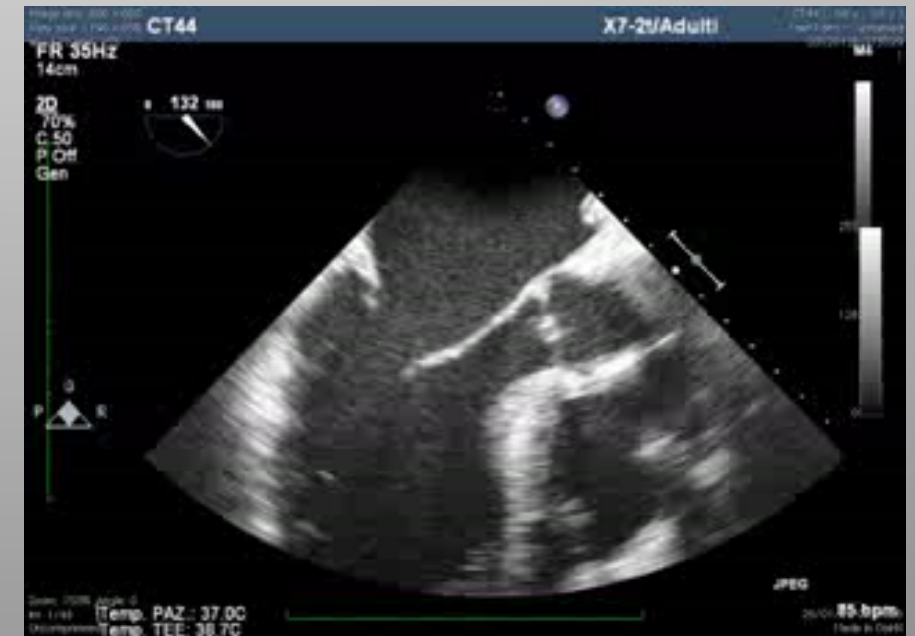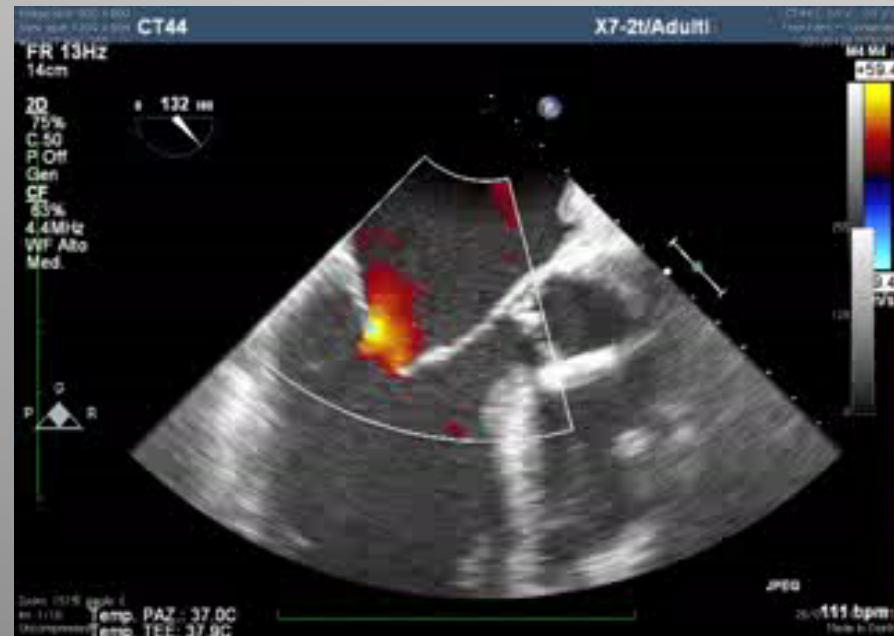
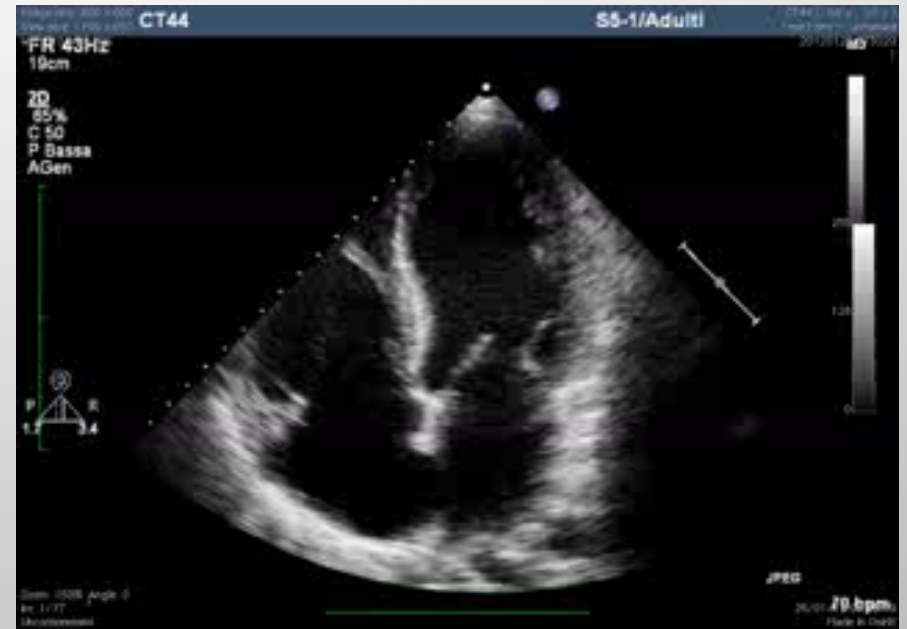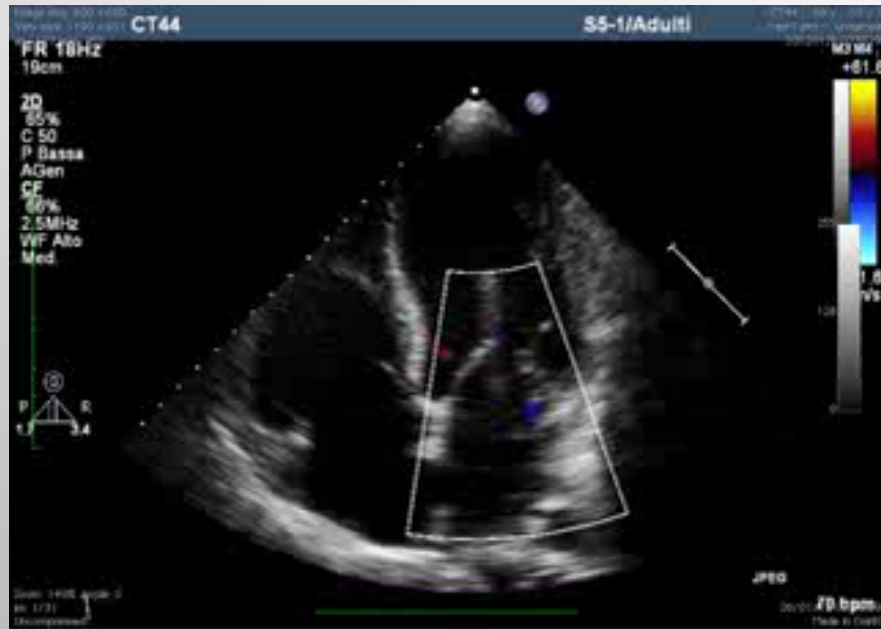
Type III B

Ischemic / Dilated
Cardiomyopathy

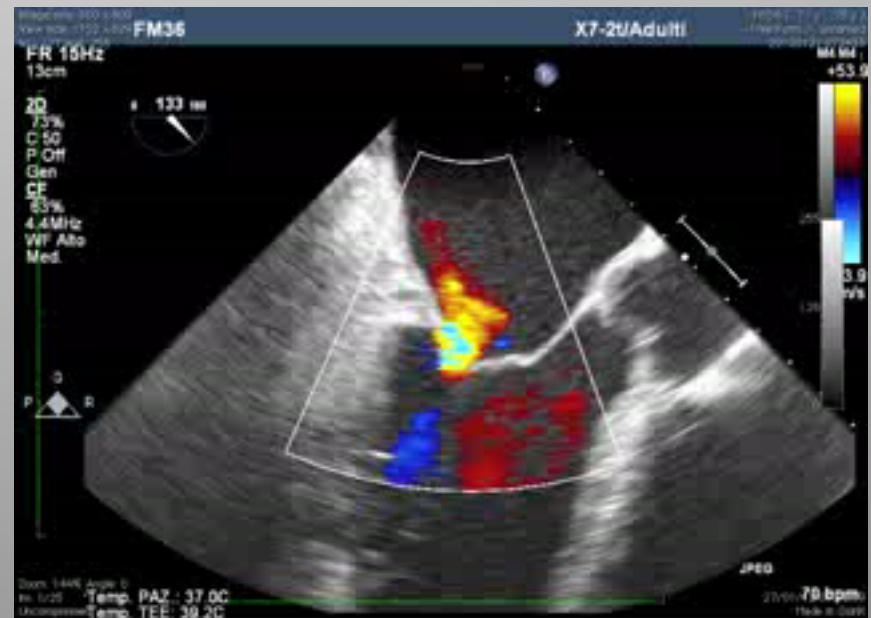
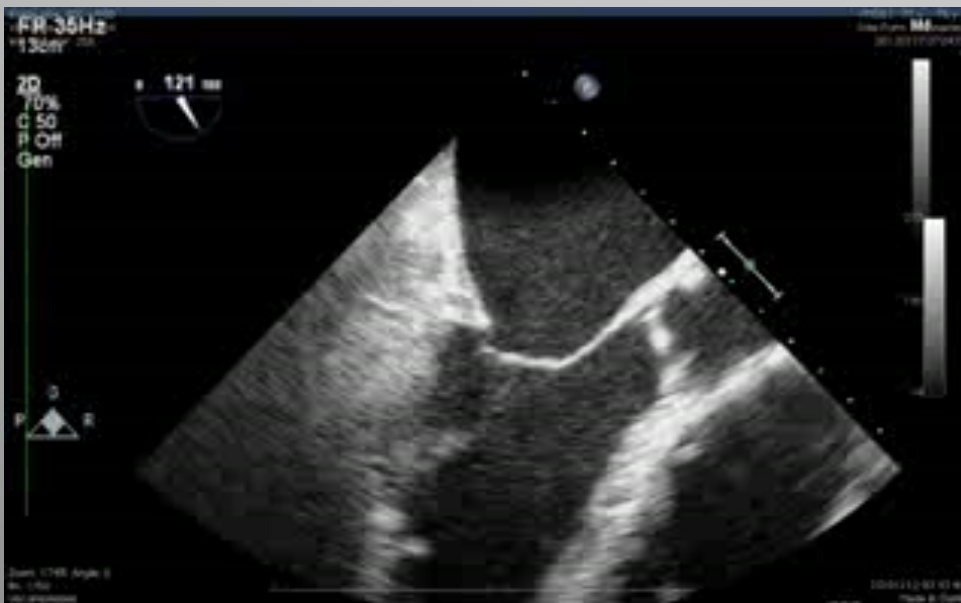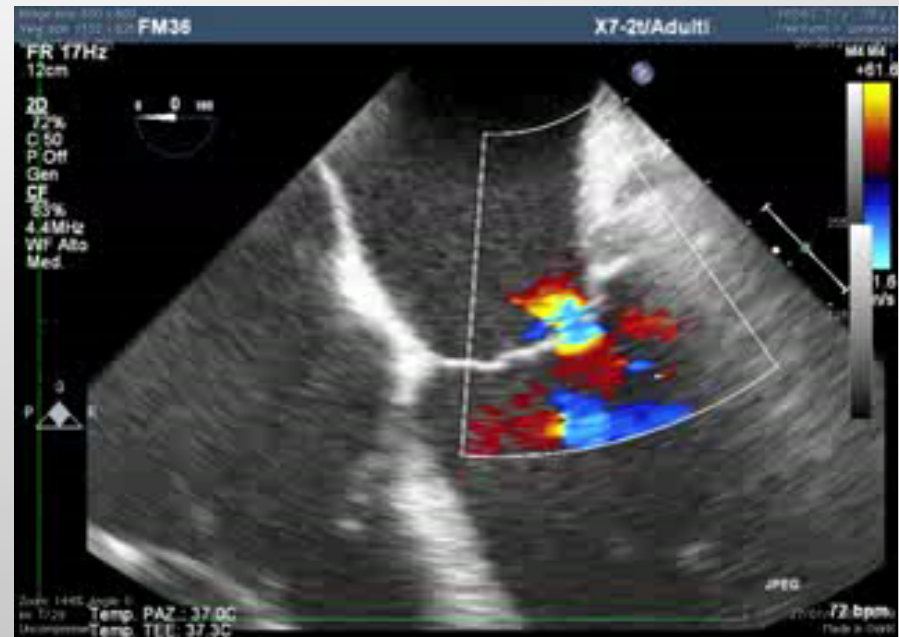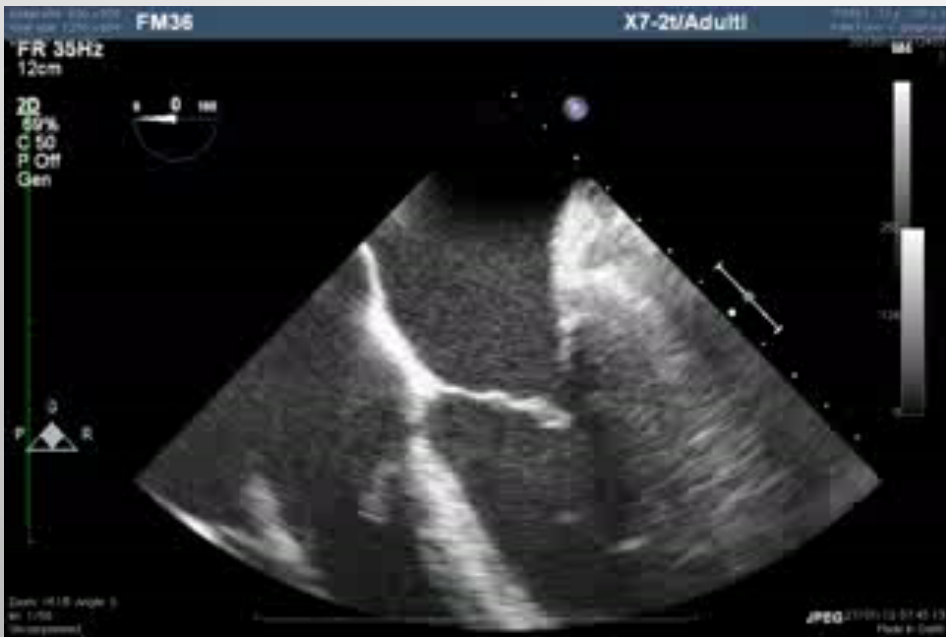Functional MR



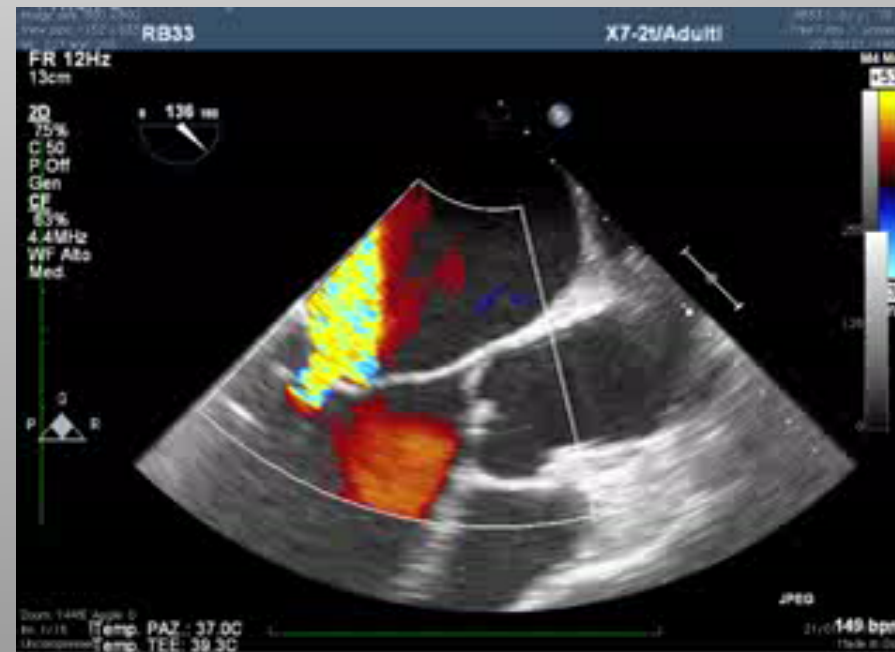
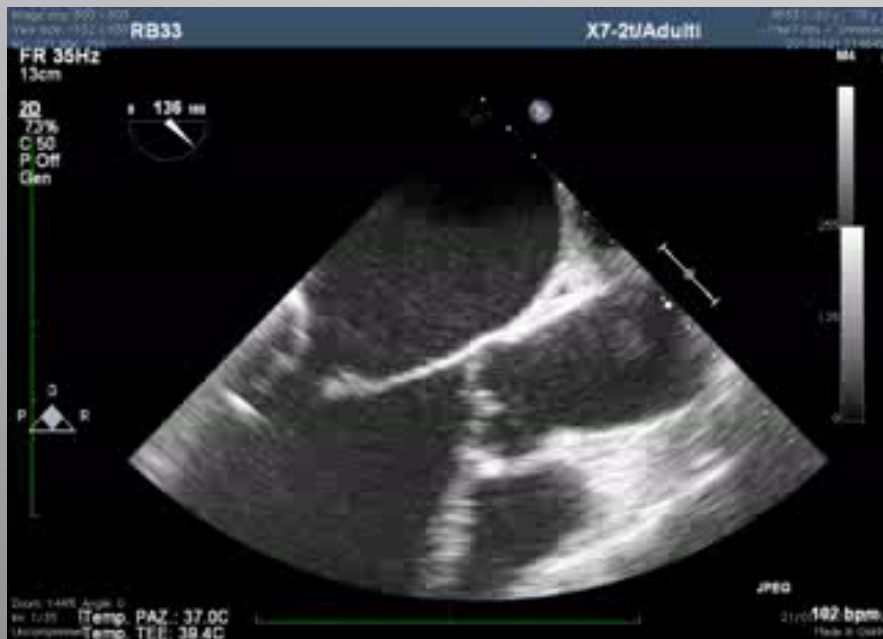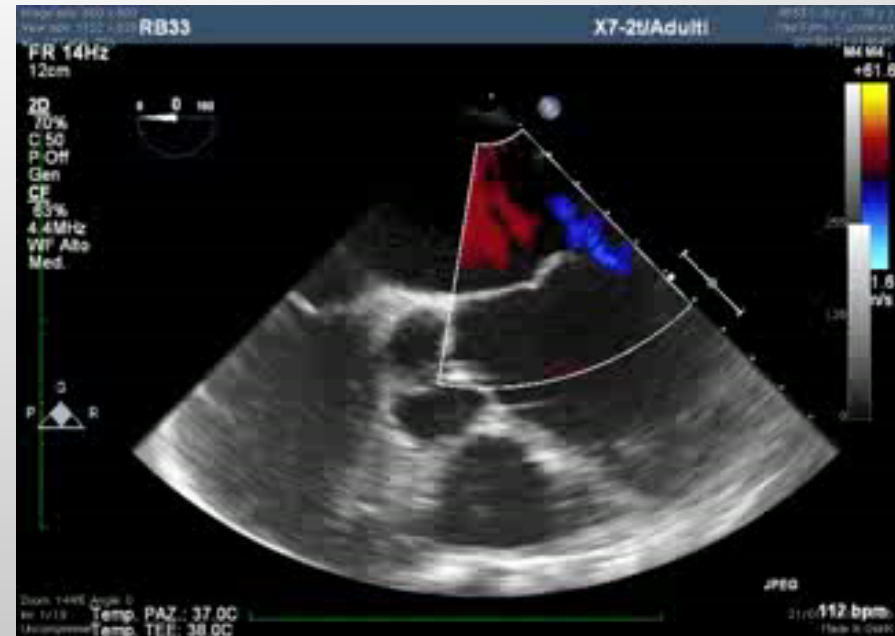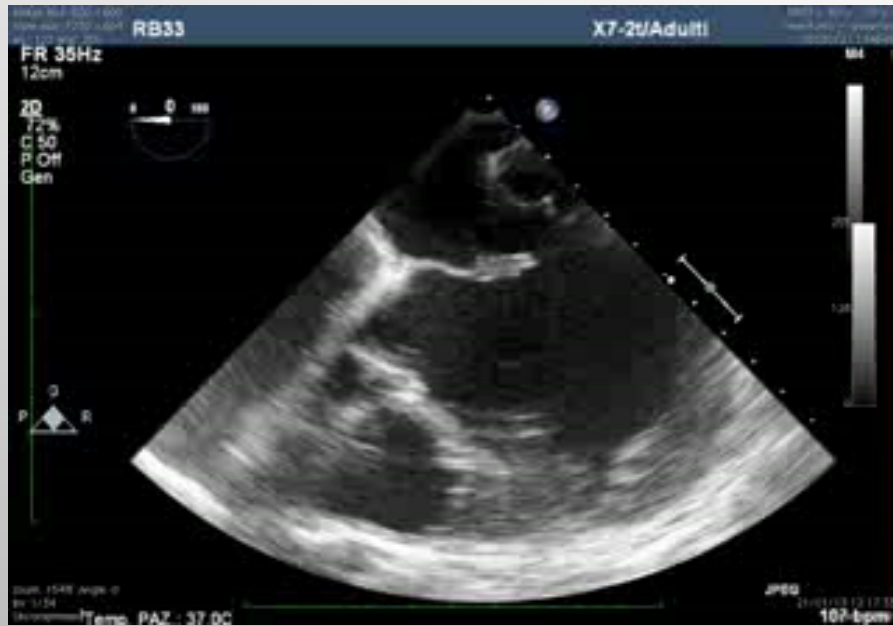Functional MR



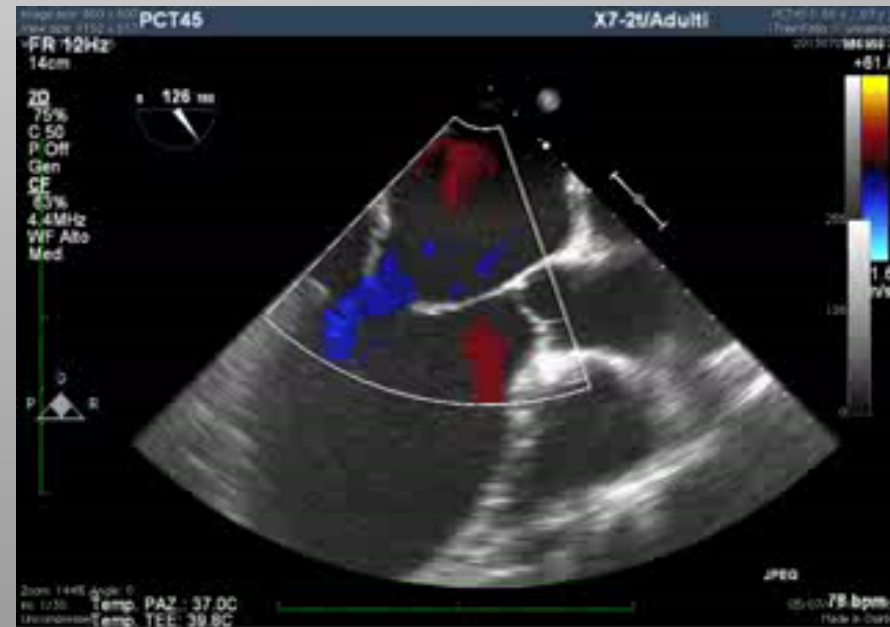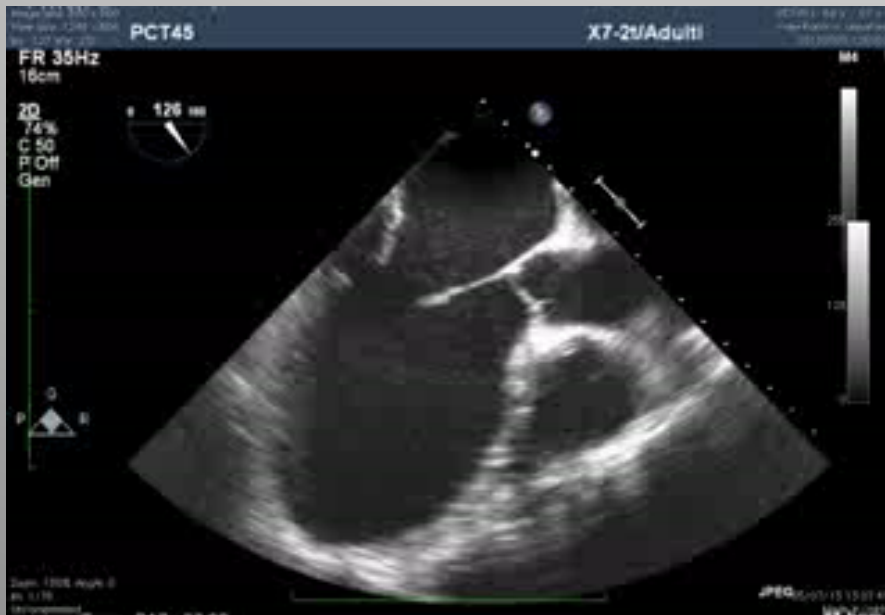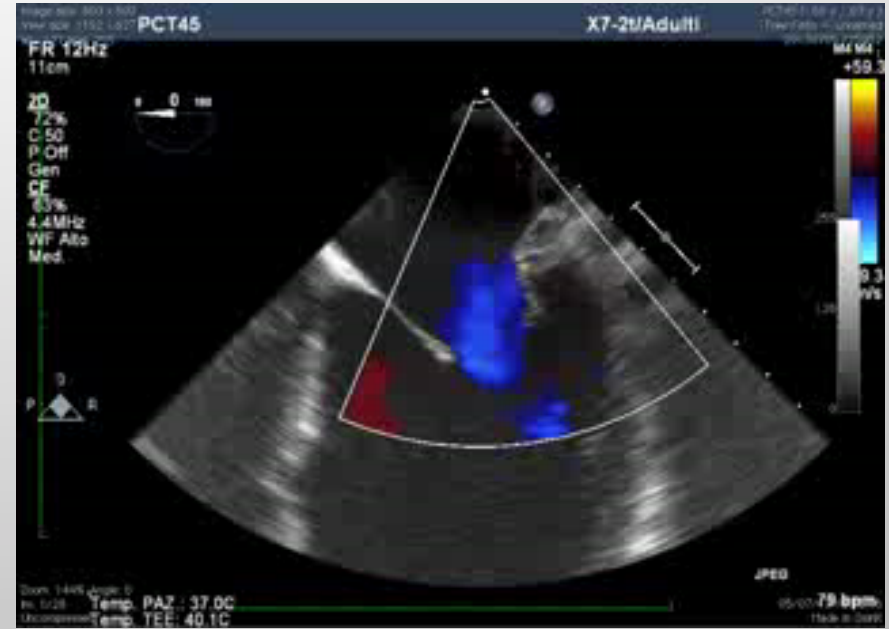
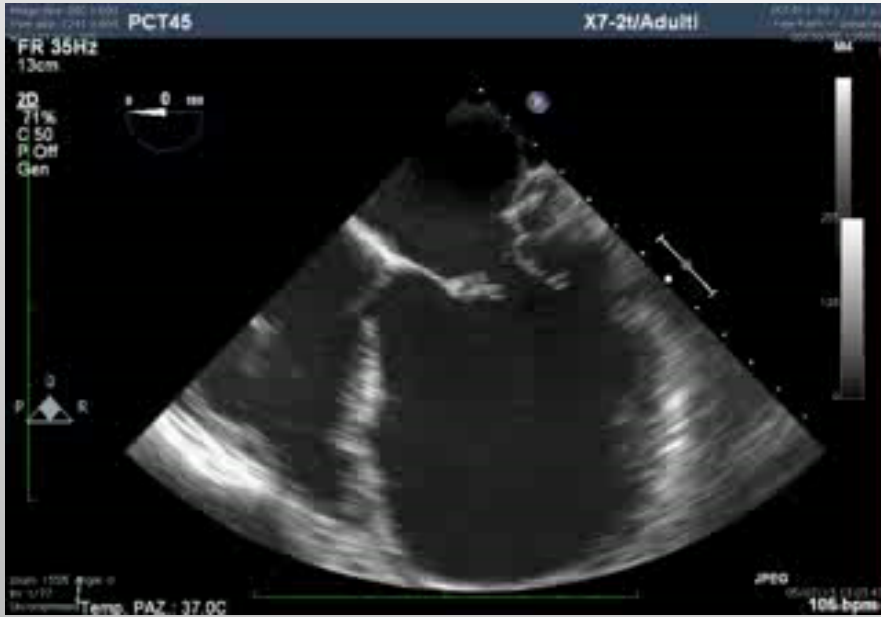Functional MR



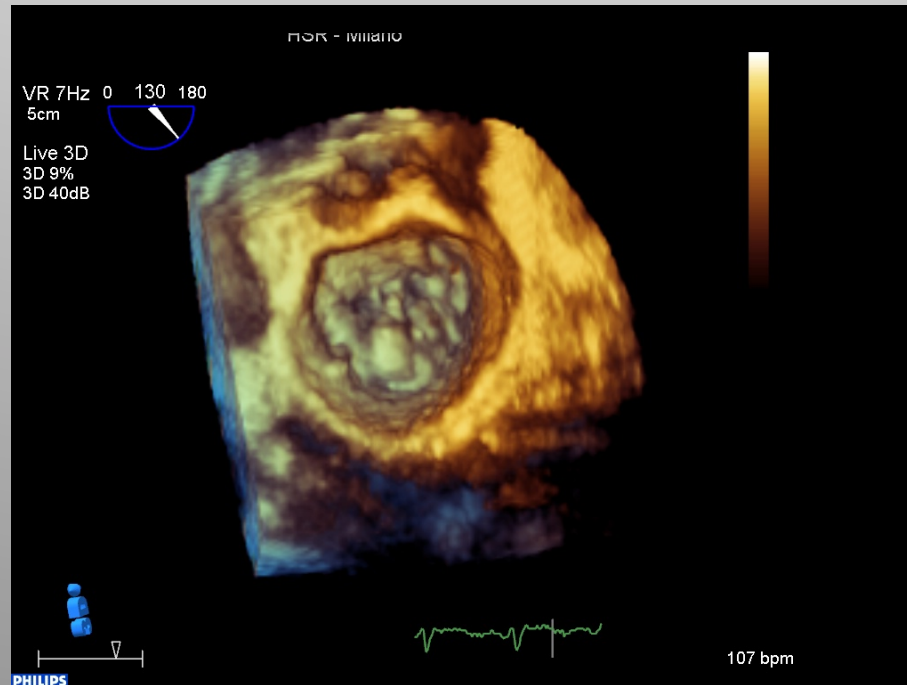
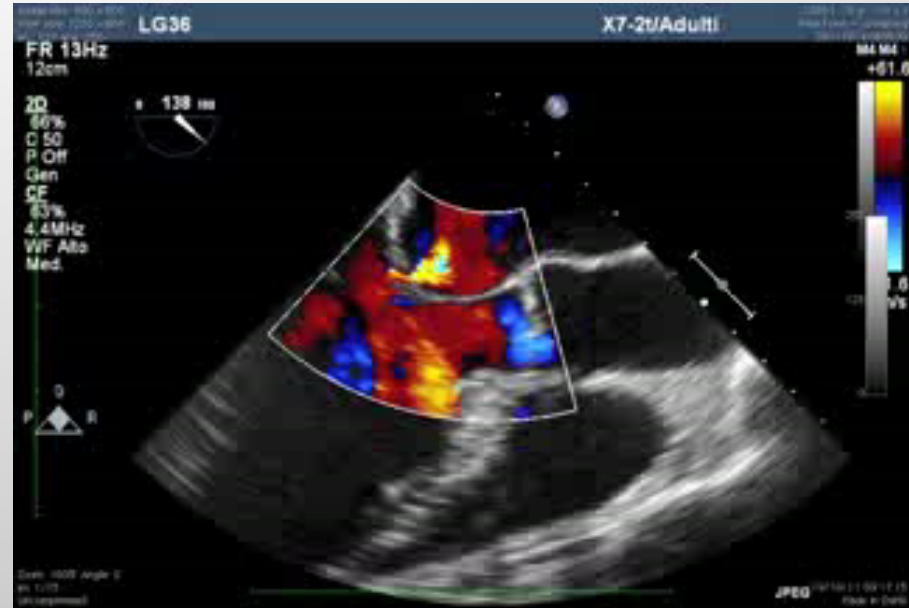
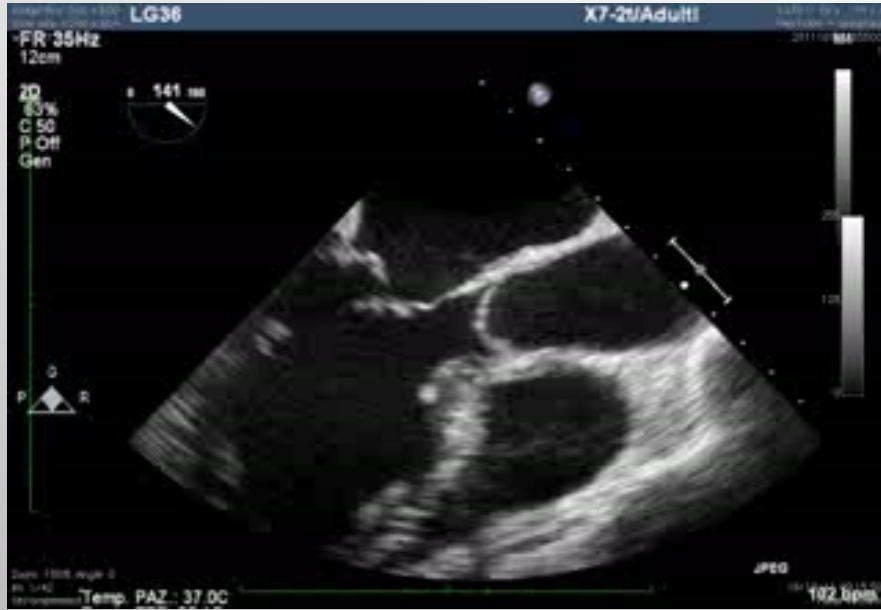Functional MR



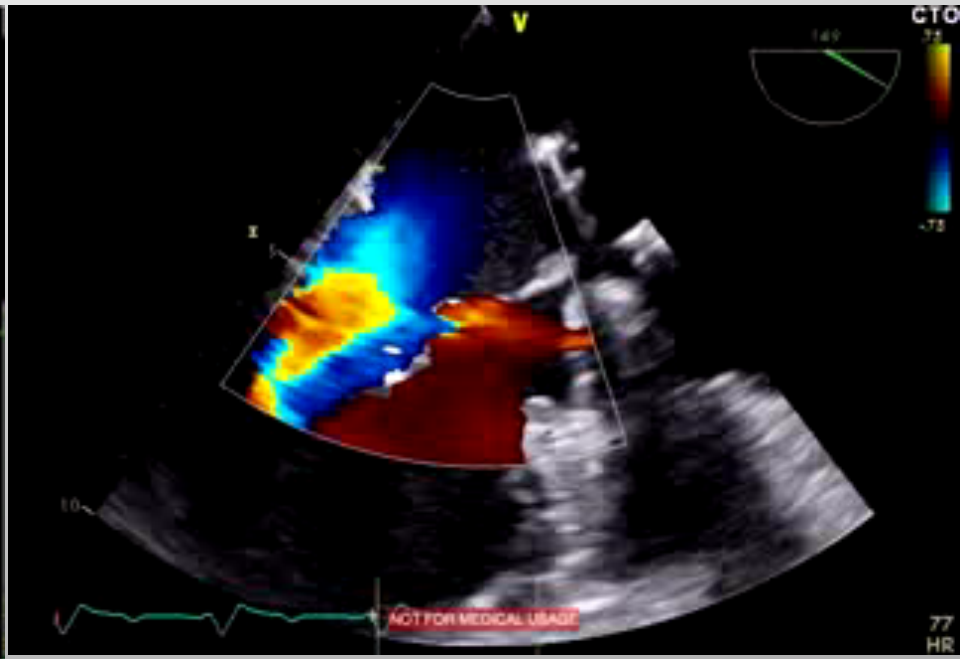
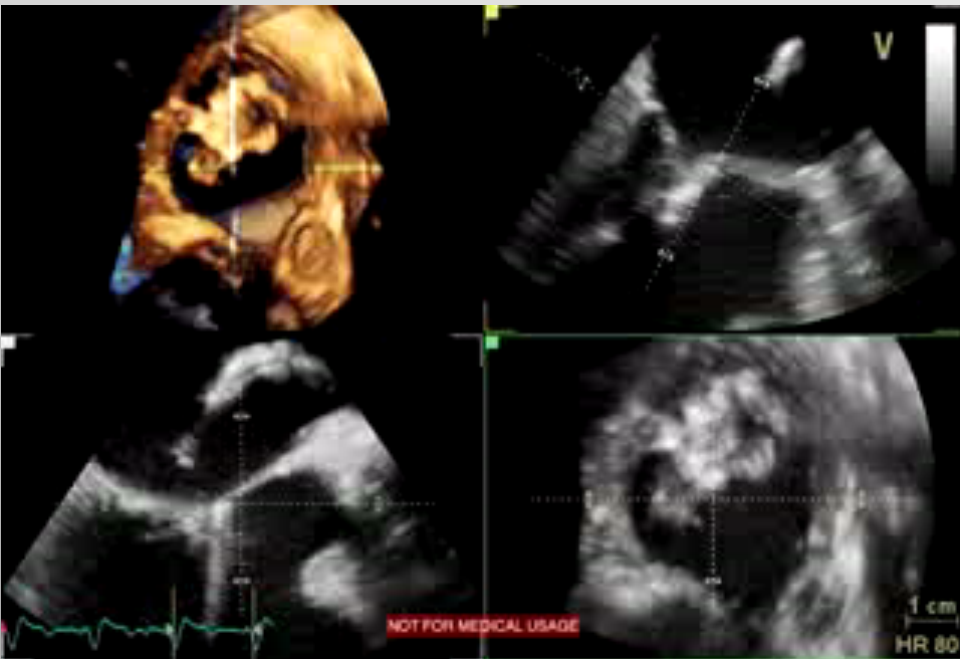
Functional MR



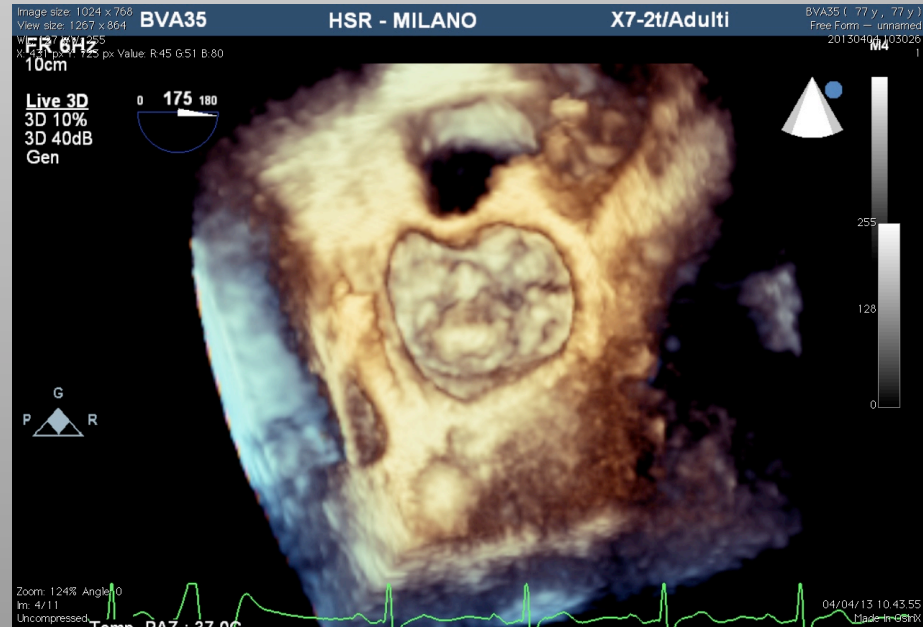
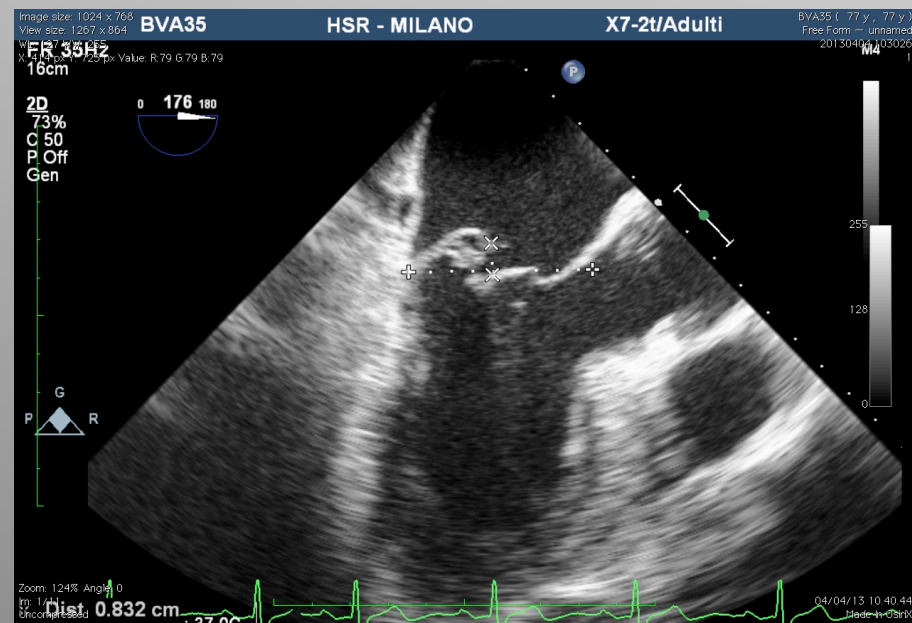
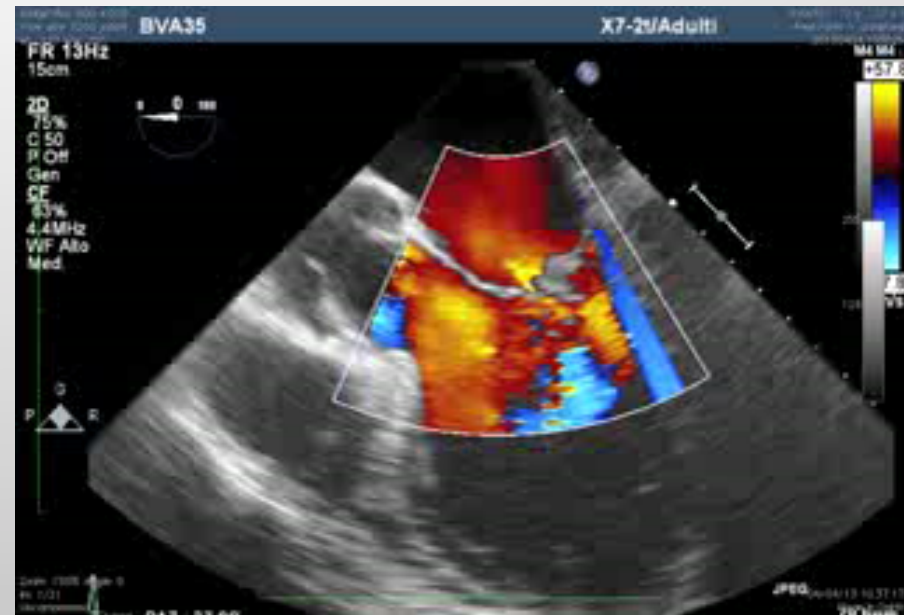
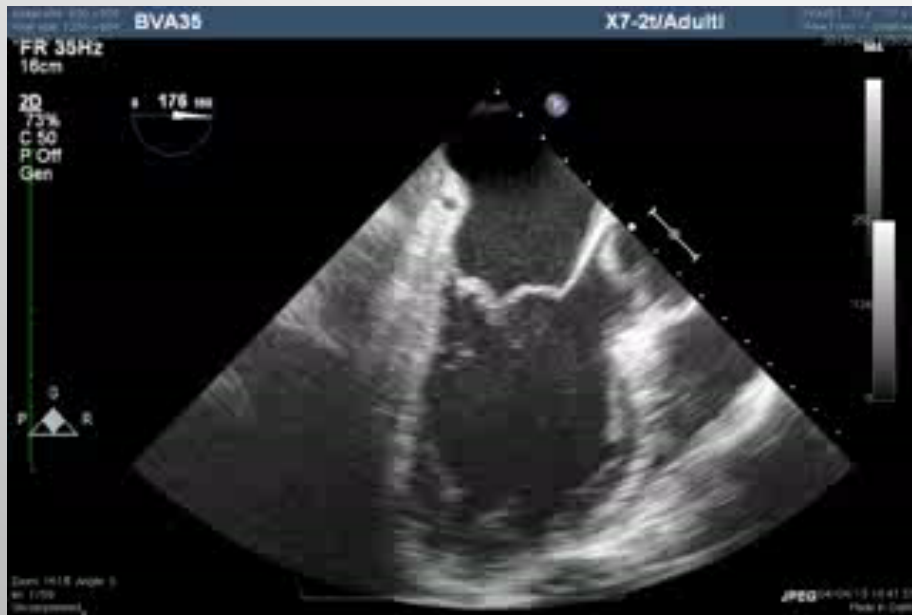Organic MR



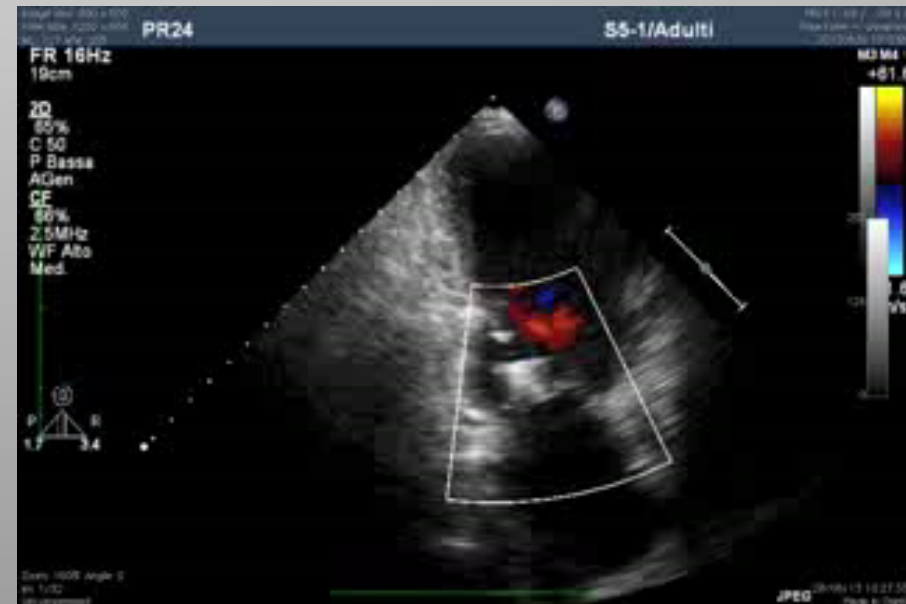
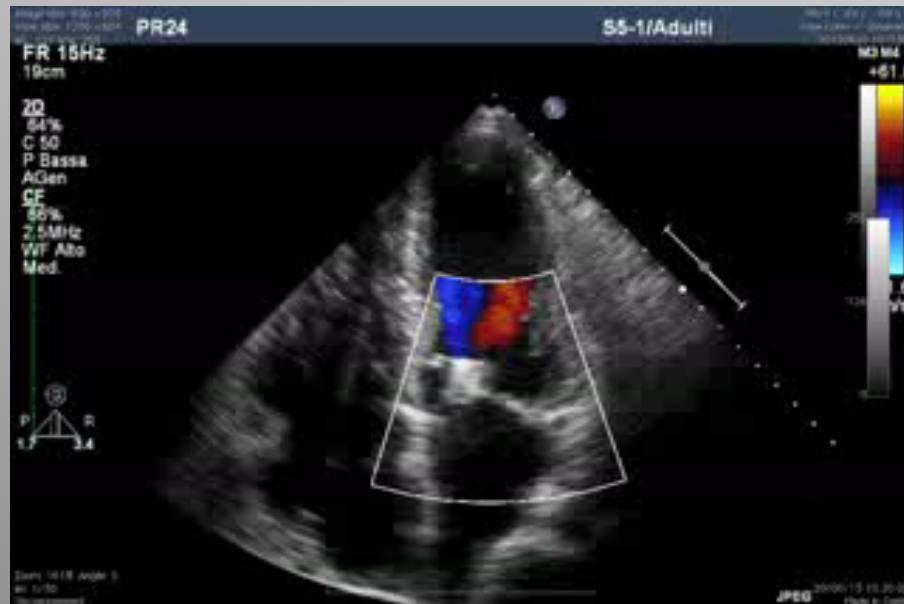
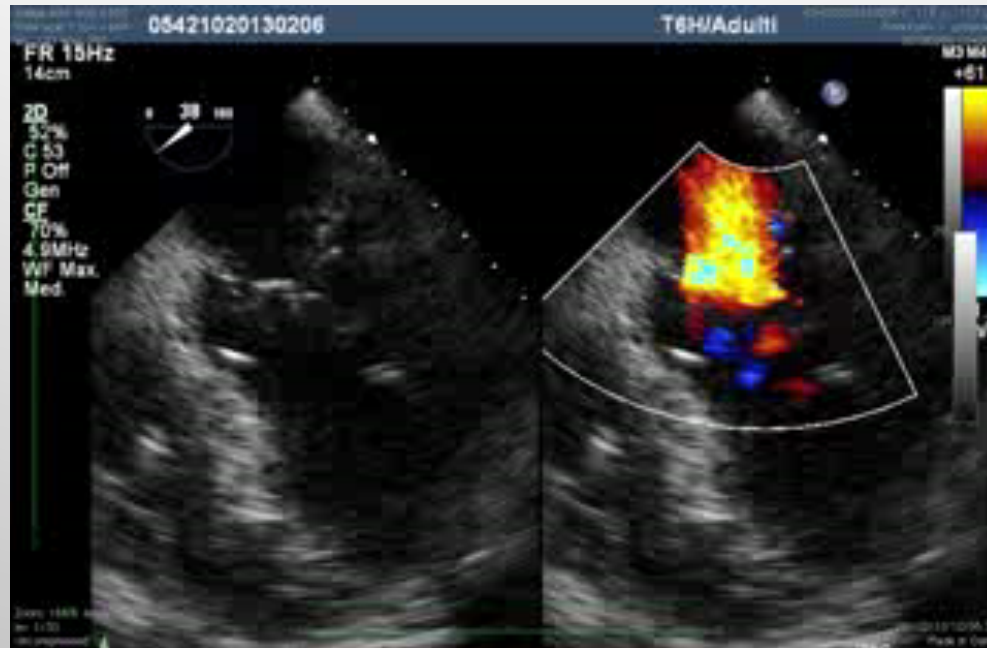
Organic MR



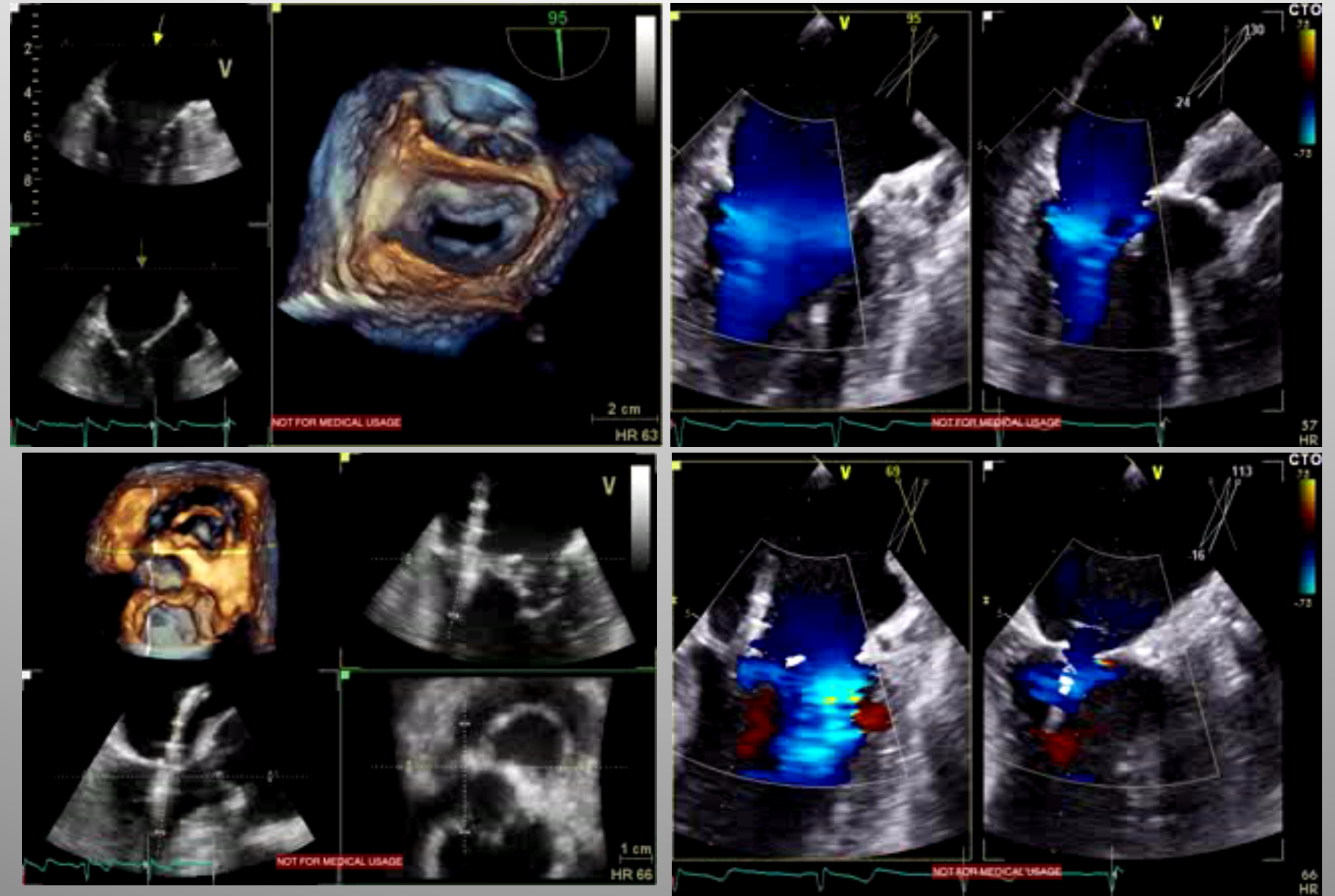
Organic MR



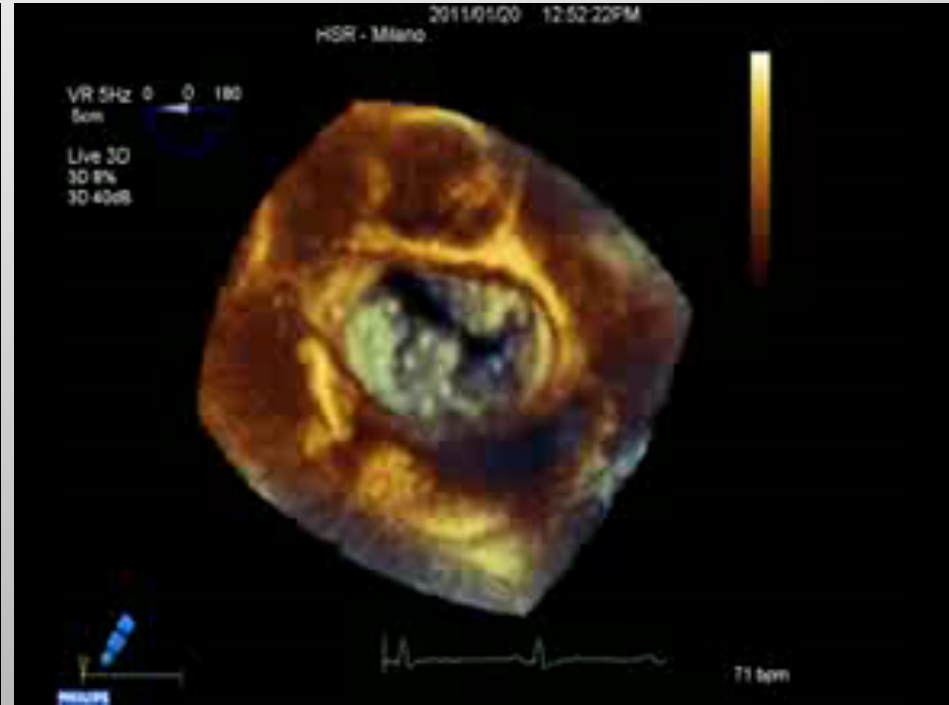
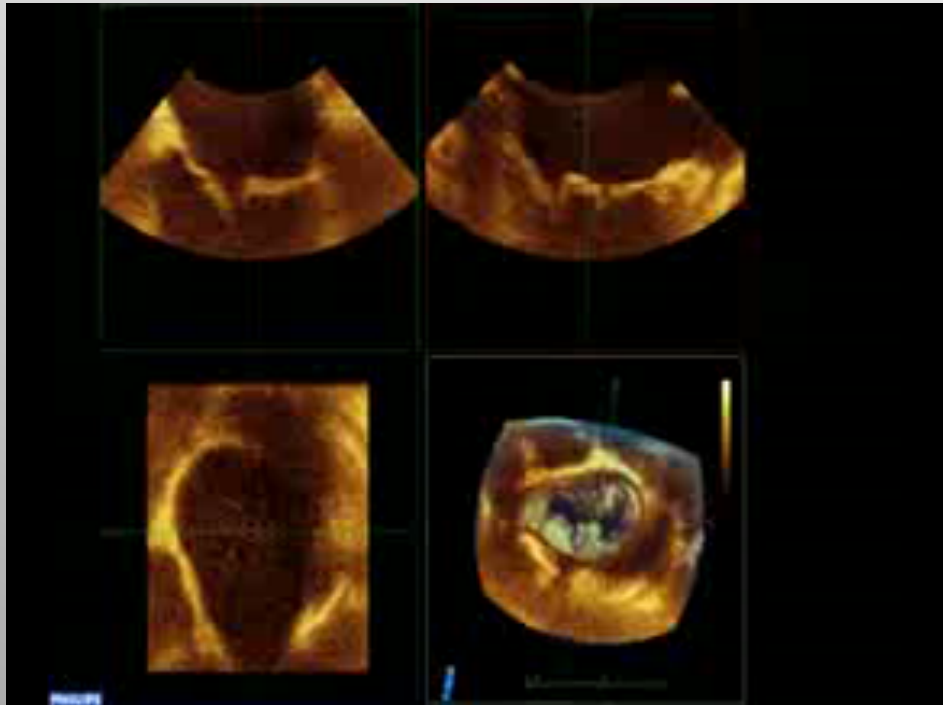
Organic MR



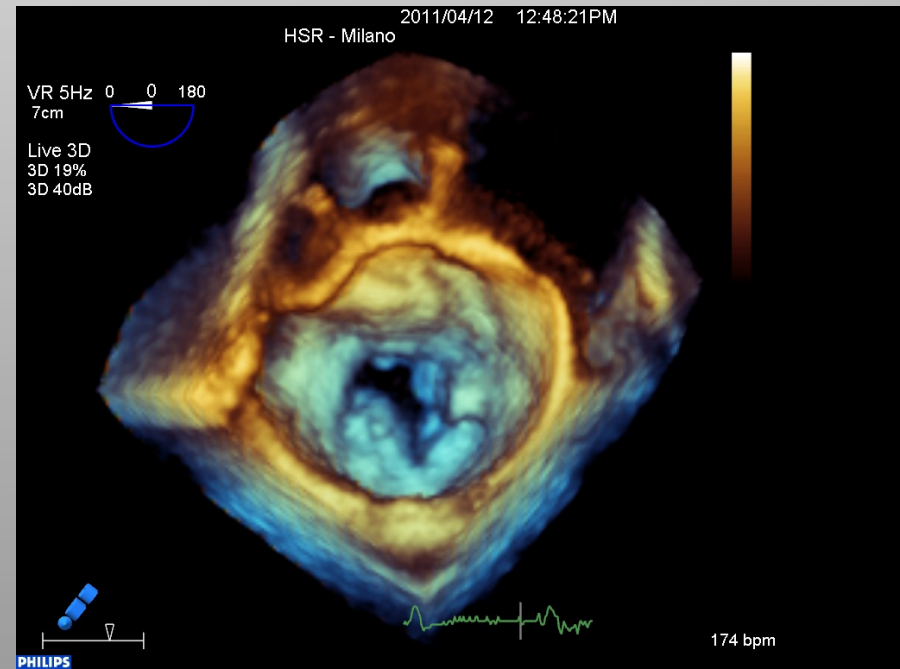
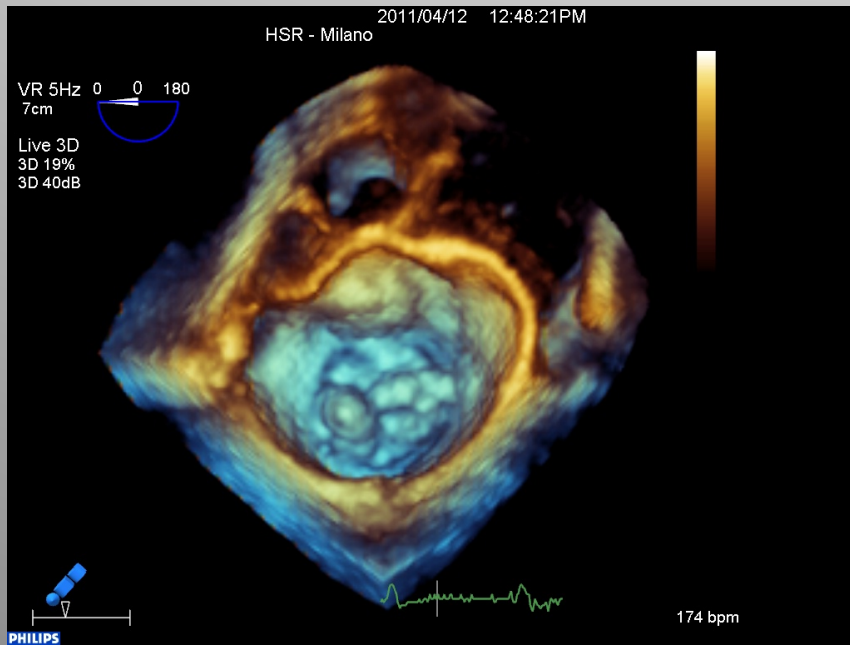
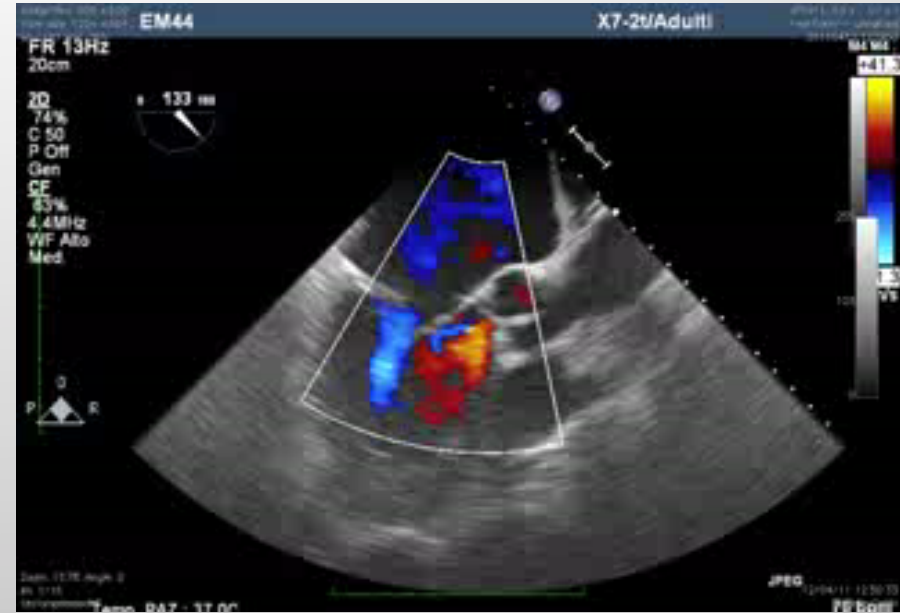
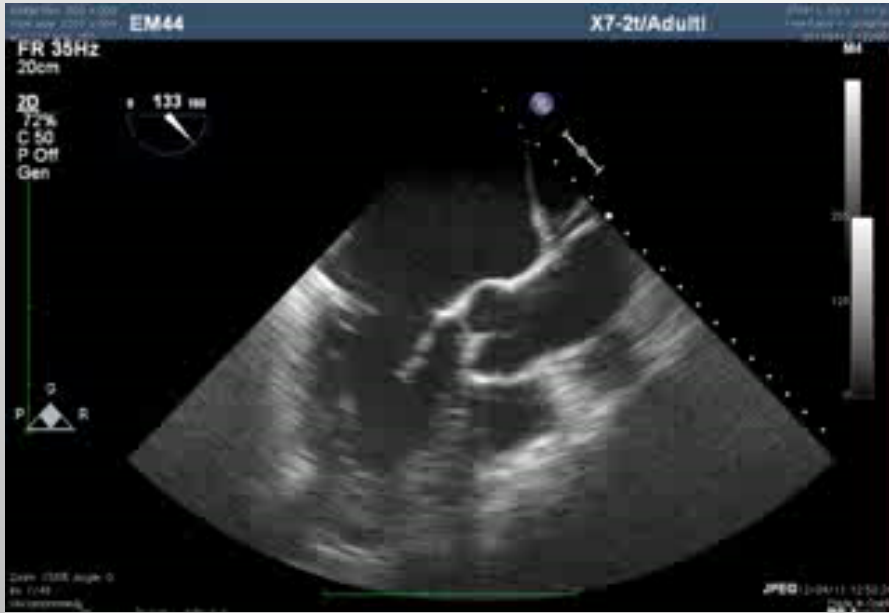
Organic MR



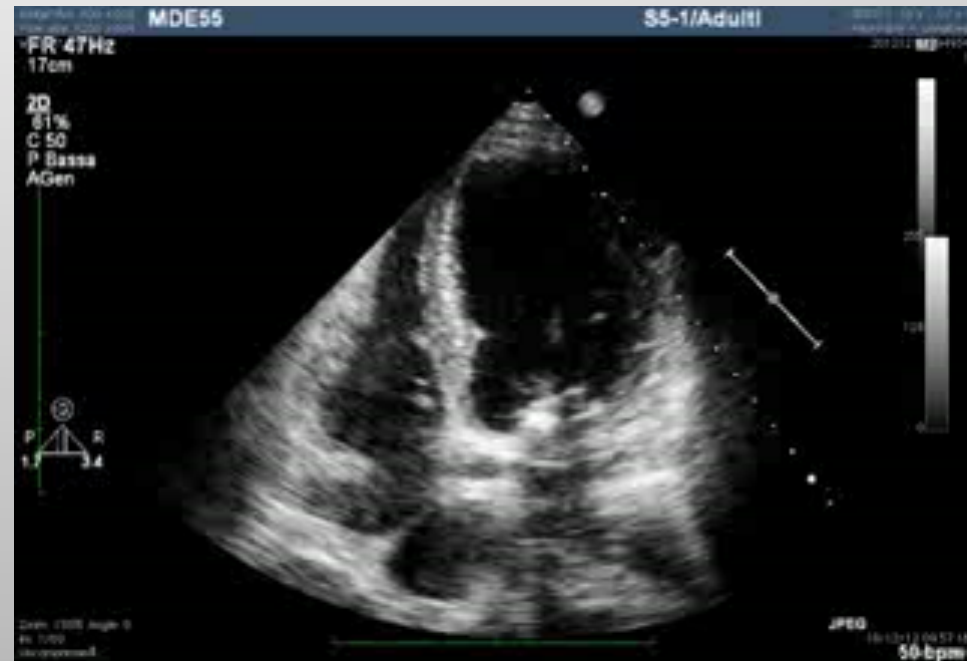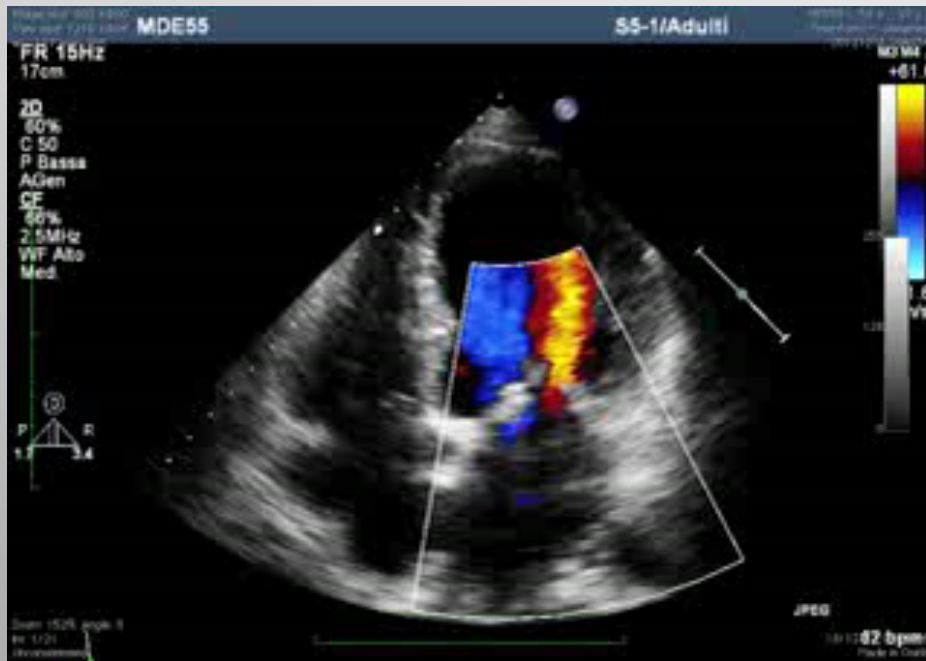
Organic MR



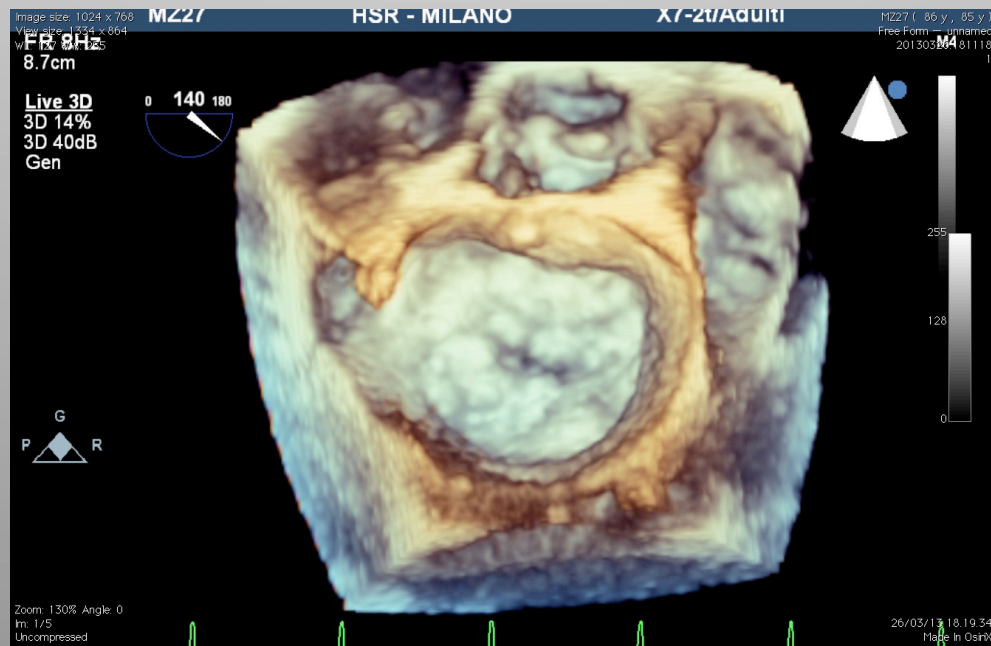
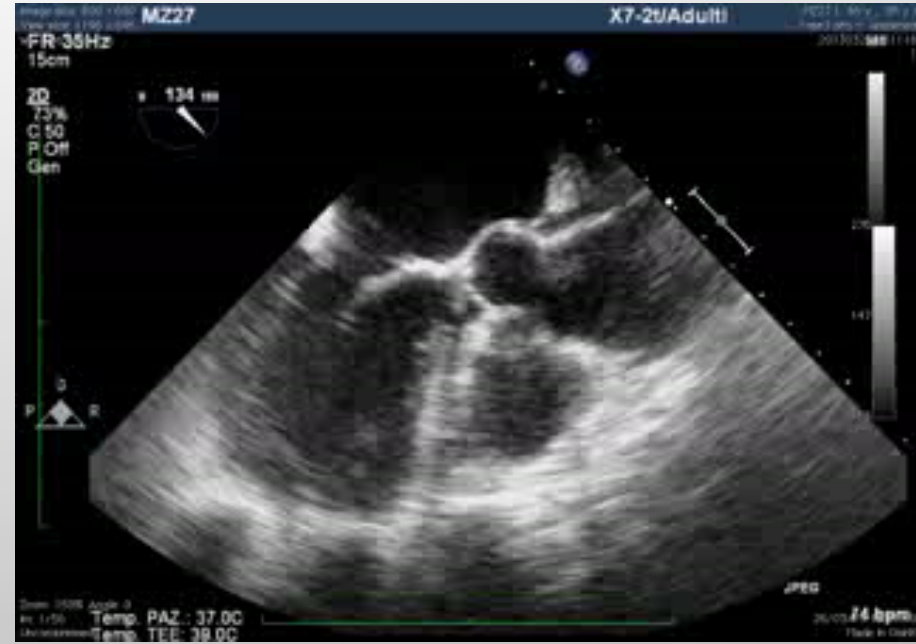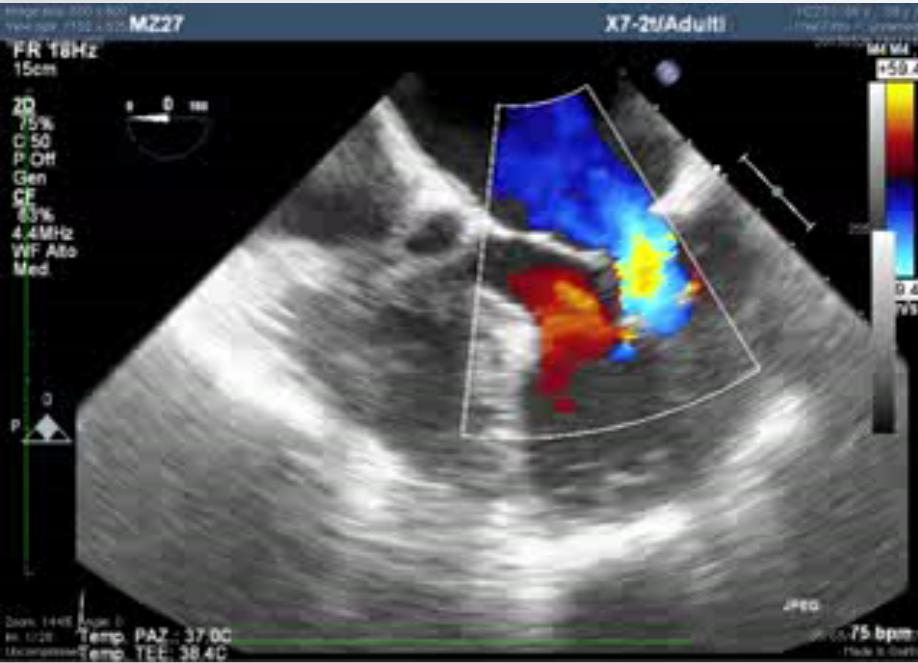
Organic MR



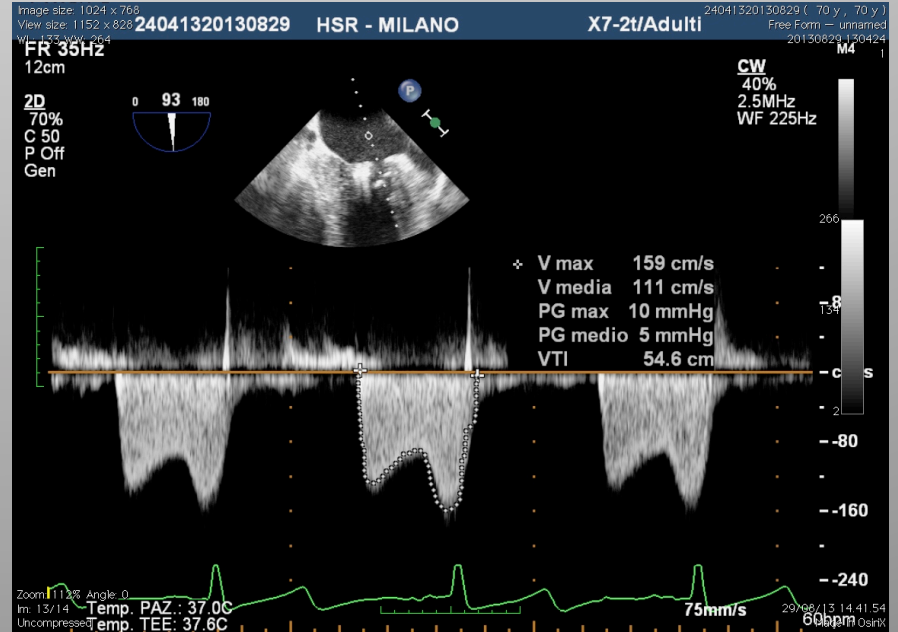
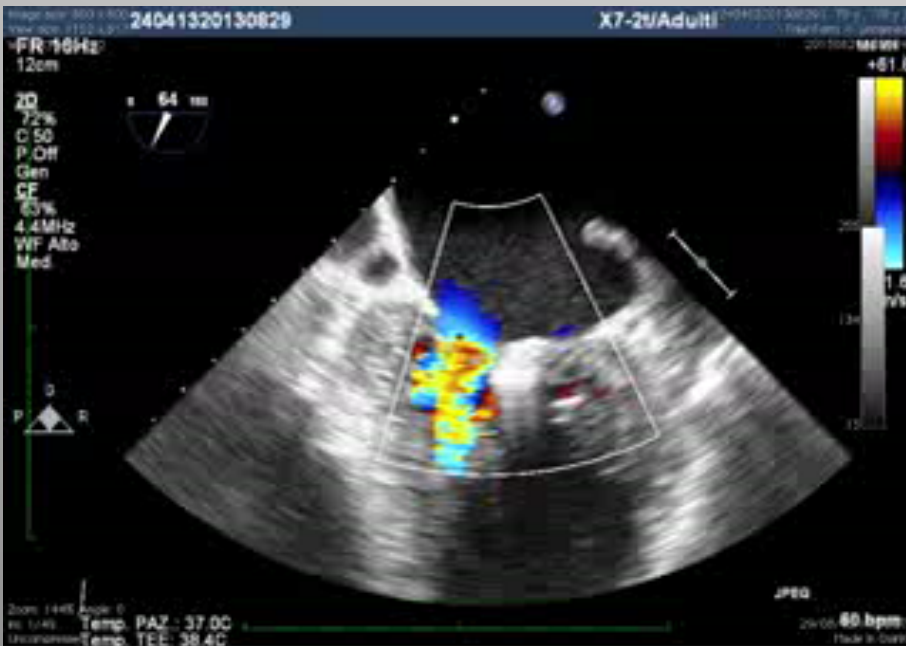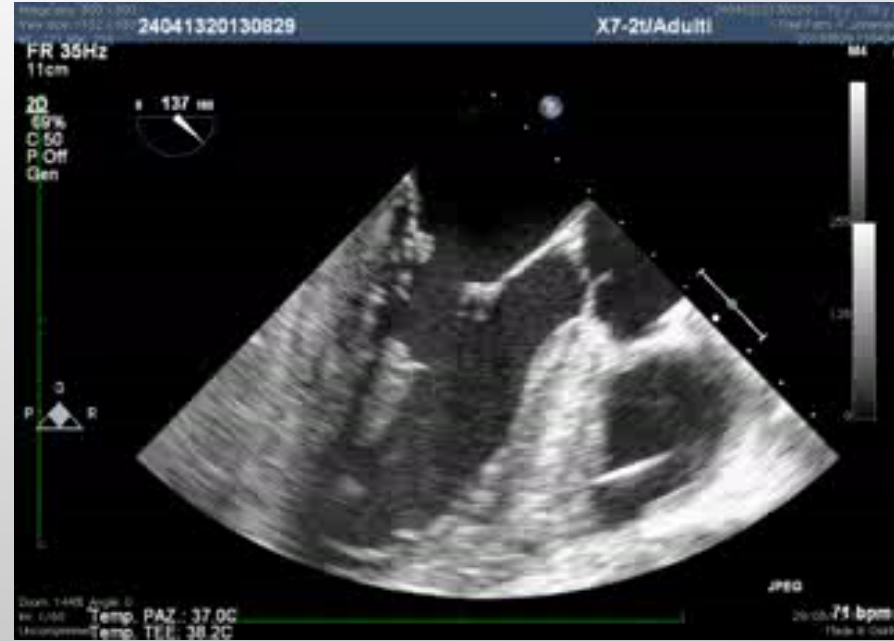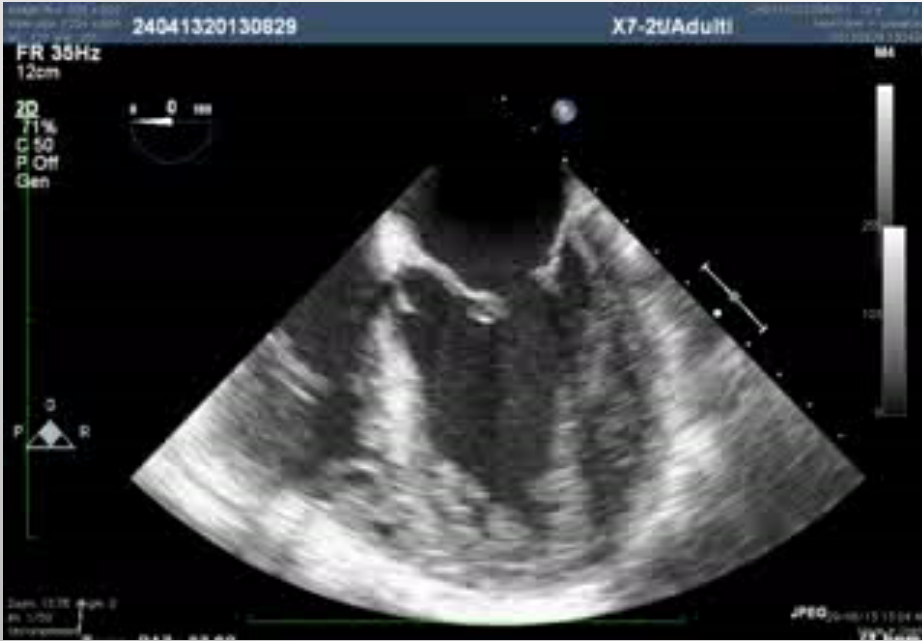Organic MR



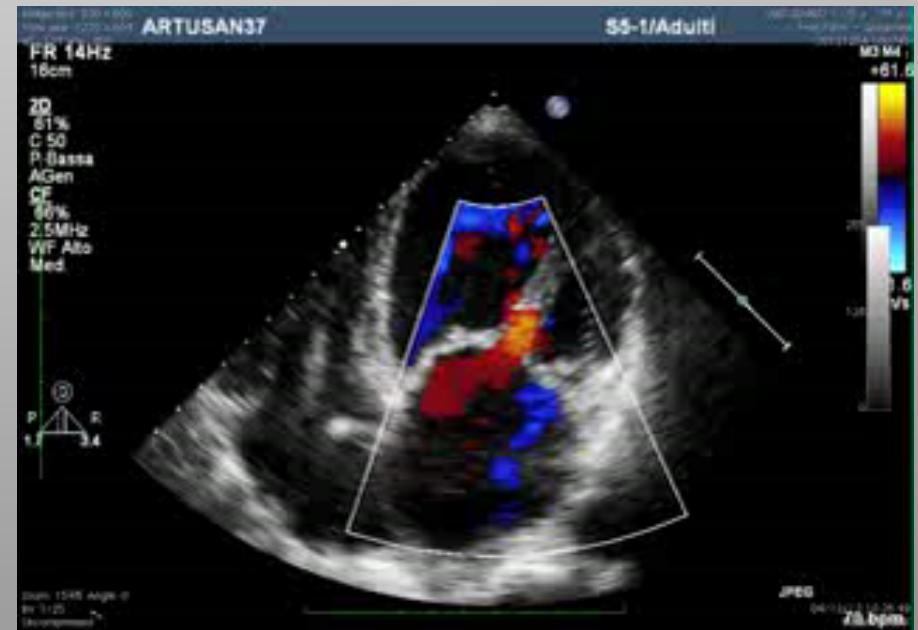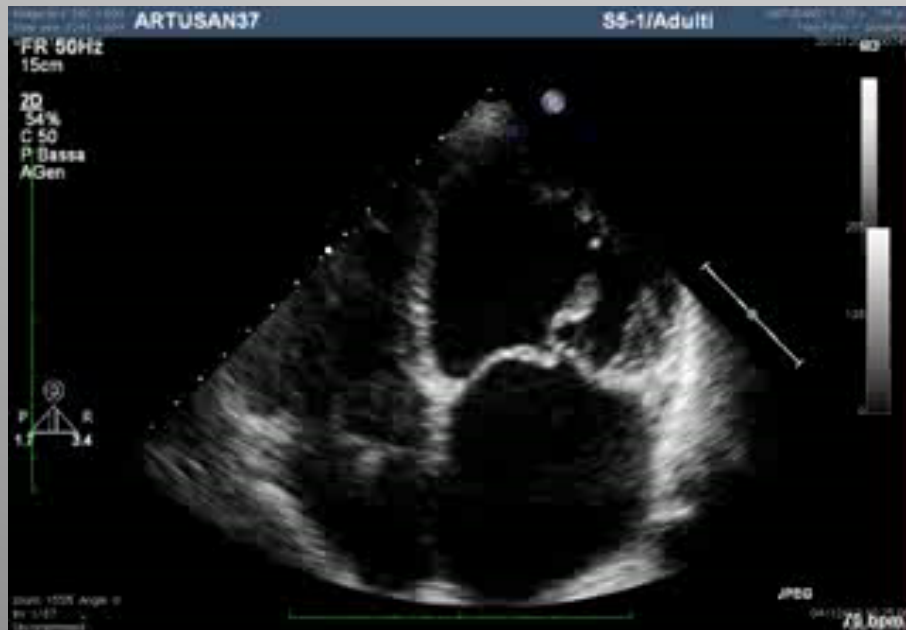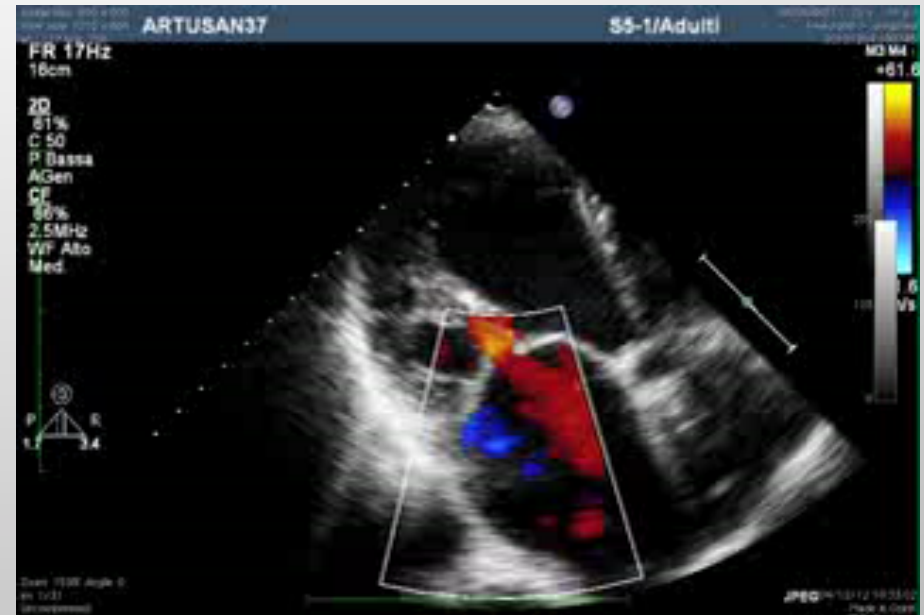
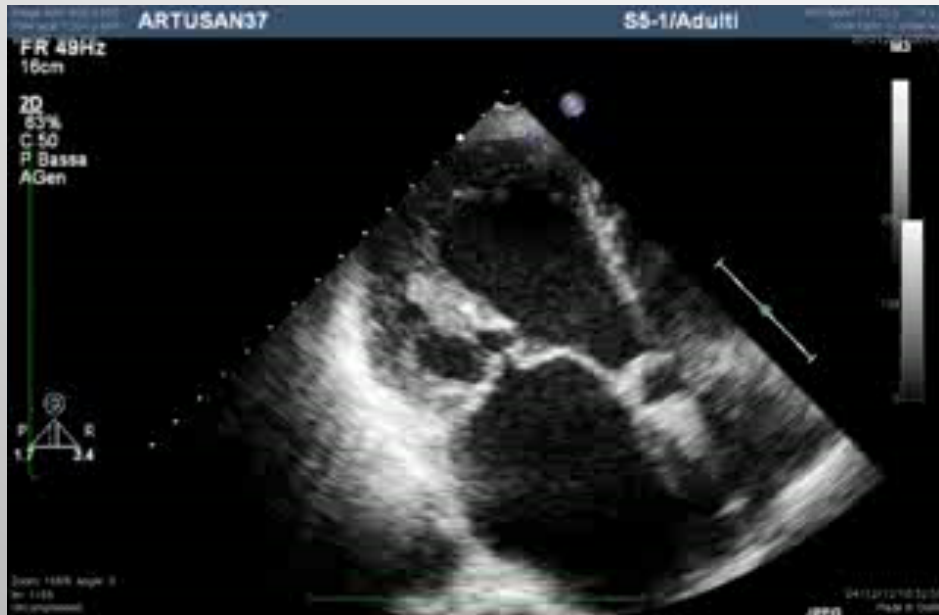Organic MR



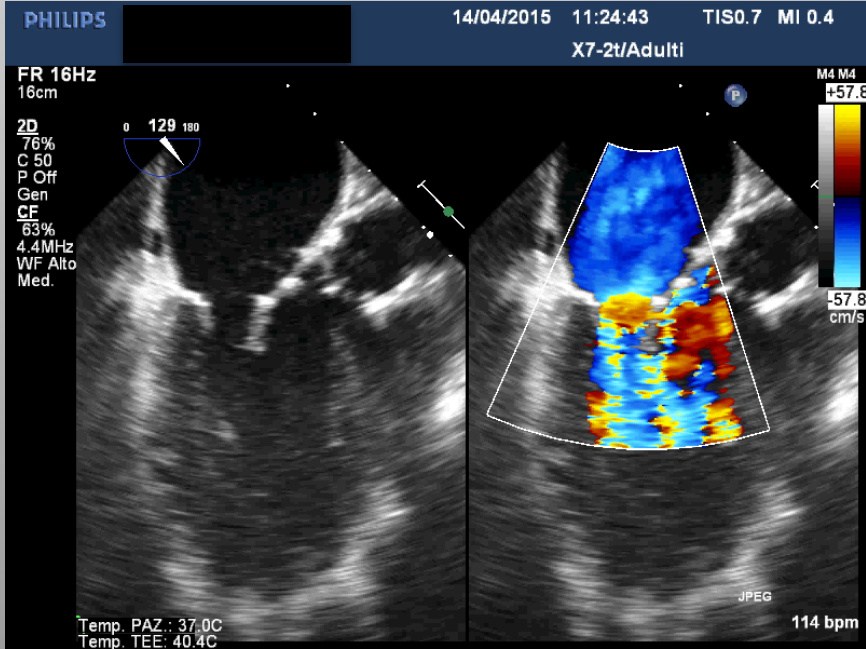
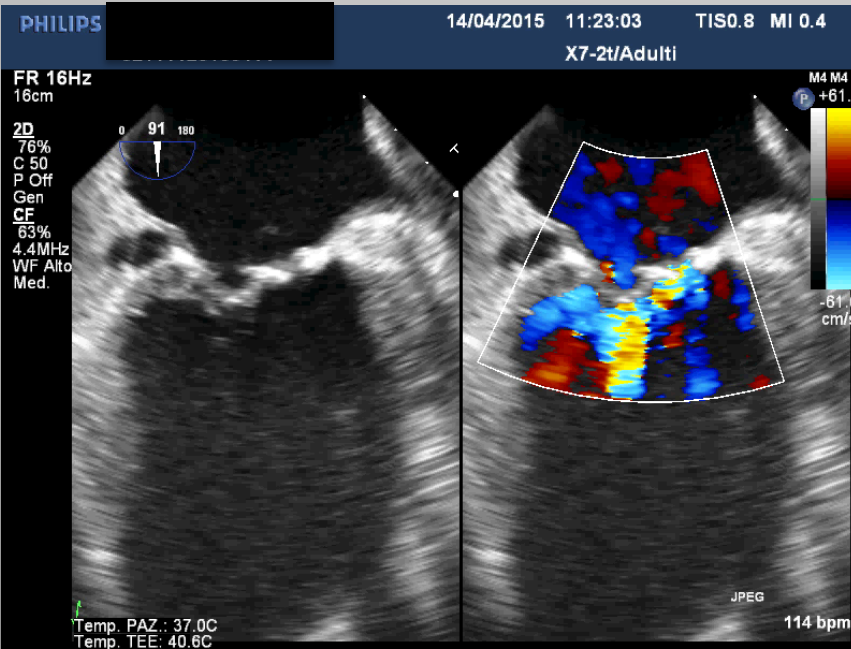
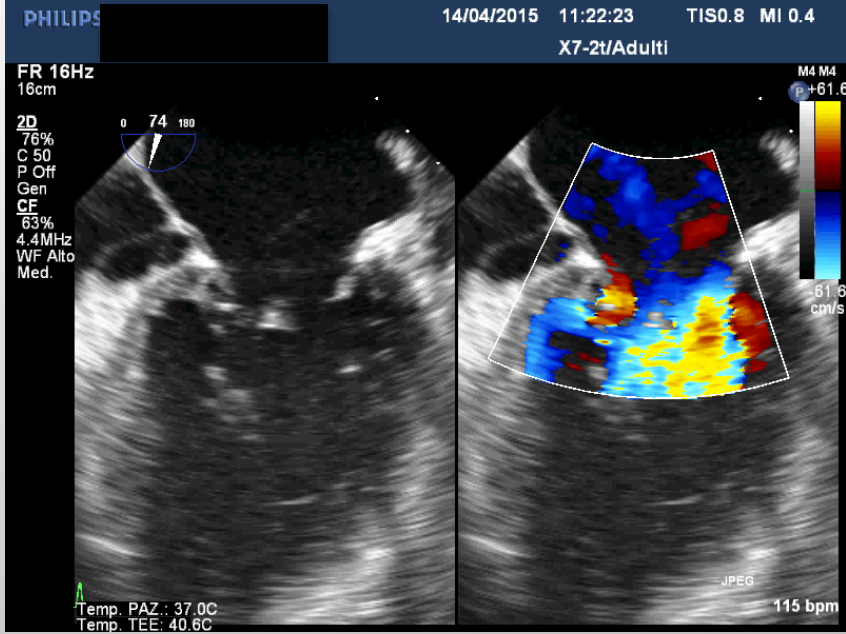
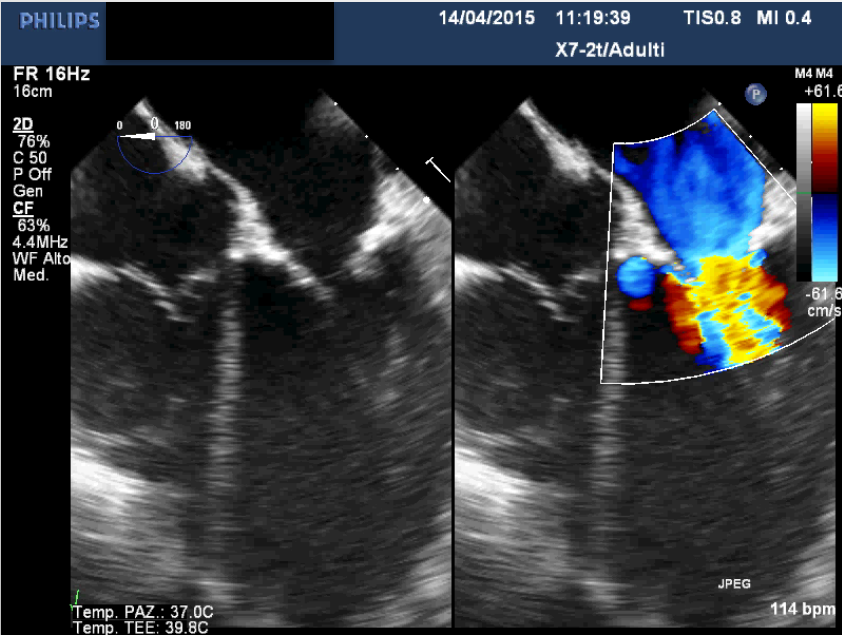
Organic MR



Organic MR



Organic MR



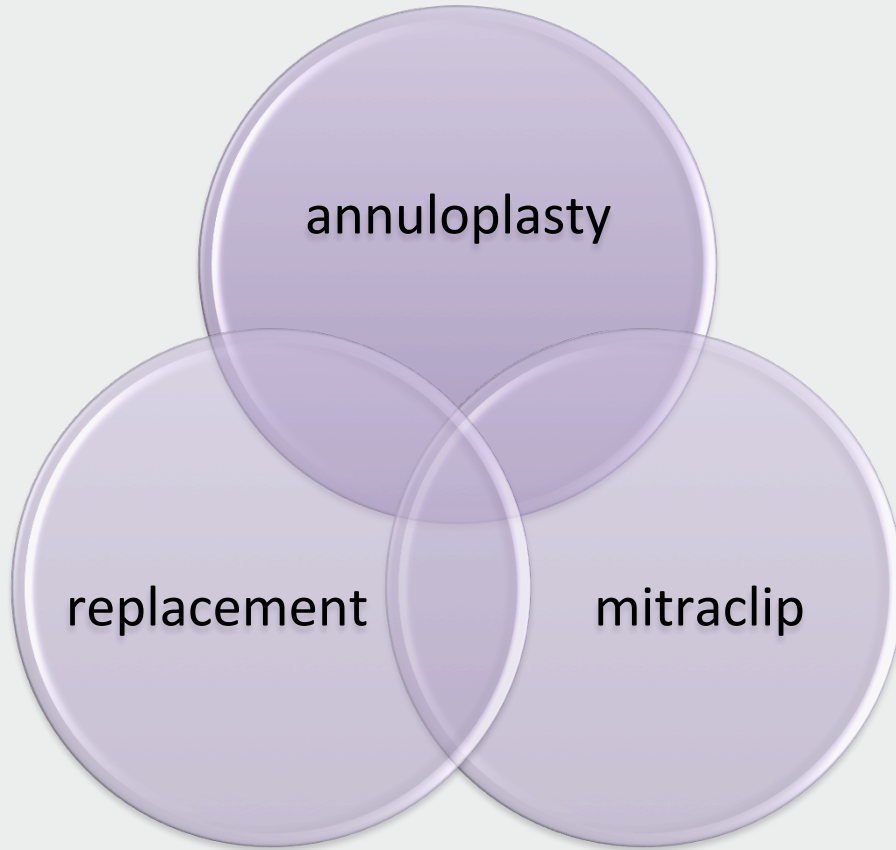
Conclusions

1. EVEREST Criteria \longrightarrow Non restrictive

2. Etiology \neq Functional Anatomy \longrightarrow Personalized
evaluation of the MV

Conclusions

The complementary role of transcatheter techniques



- **Stand-alone annuloplasty:** early treatment FMR /symmetric tethering
- **Stand-alone Mitraclip:** FMR with asymmetric tethering (IMR)
- **Stand-alone Mitraclip:** DMR with little annular dilatation
- **Combined Annuloplasty and MitraClip:** DMR with important annular dilatation and advanced FMR
- **MV Replacement:** advanced organic MR and advanced FMR